Dedifferentiated EC

- UC is demarcated (biphasic appearance)
  - Sheets of monotonous, dyshesive cells, oval to histiocytoid (cytology differs from EEC)
  - Scant cytoplasm, large vesicular nuclei, prominent nucleoli
  - Scant stroma (lymphoma-like)
  - May have rhabdoid cells, myxoid stroma
  - Tumor infiltrating lymphocytes
  - Glandular differentiation is absent
  - CK/EMA staining negative or focal (and intense)

Dedifferentiated EC

Endometrial biopsy

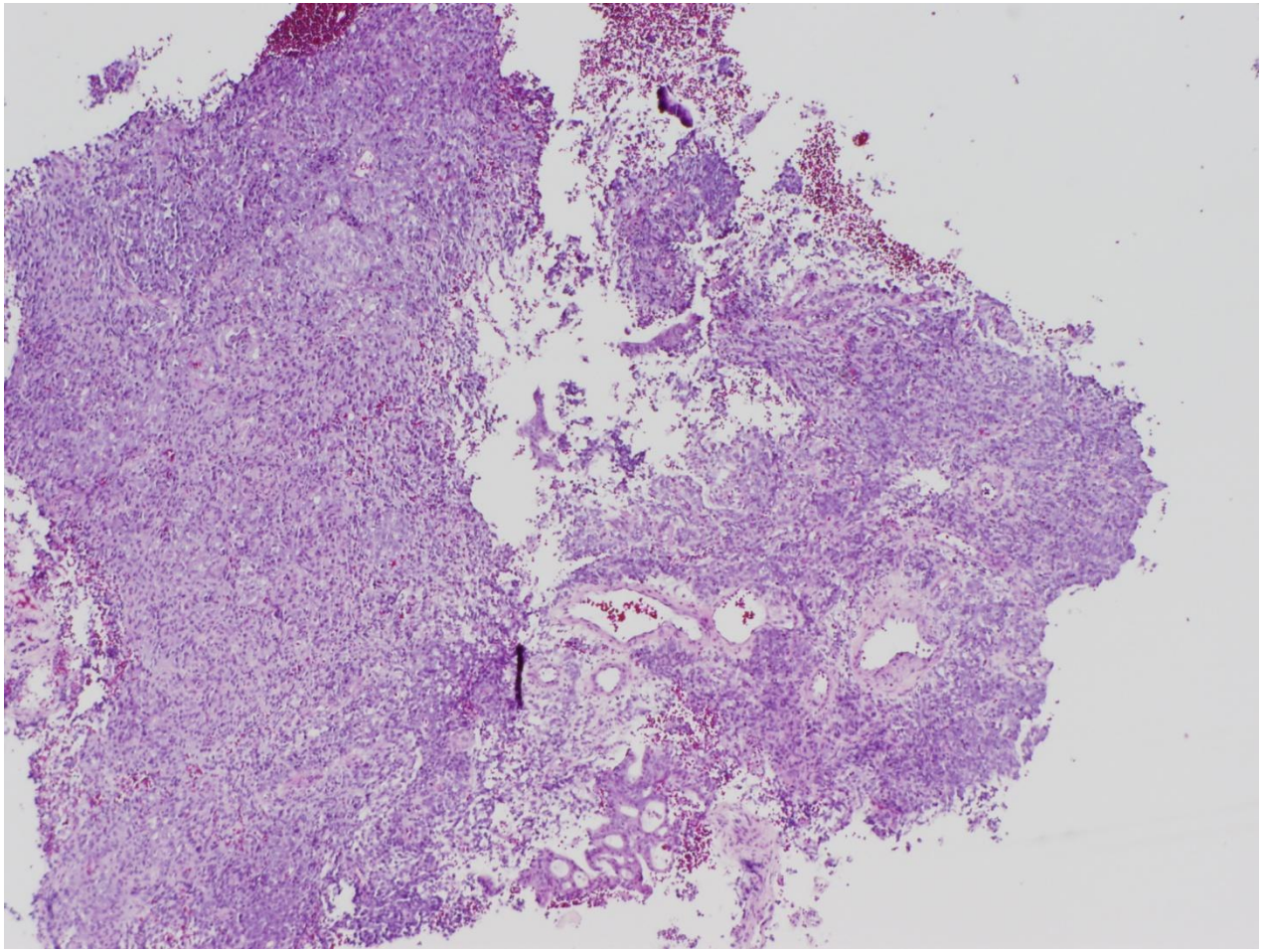

Dedifferentiated EC

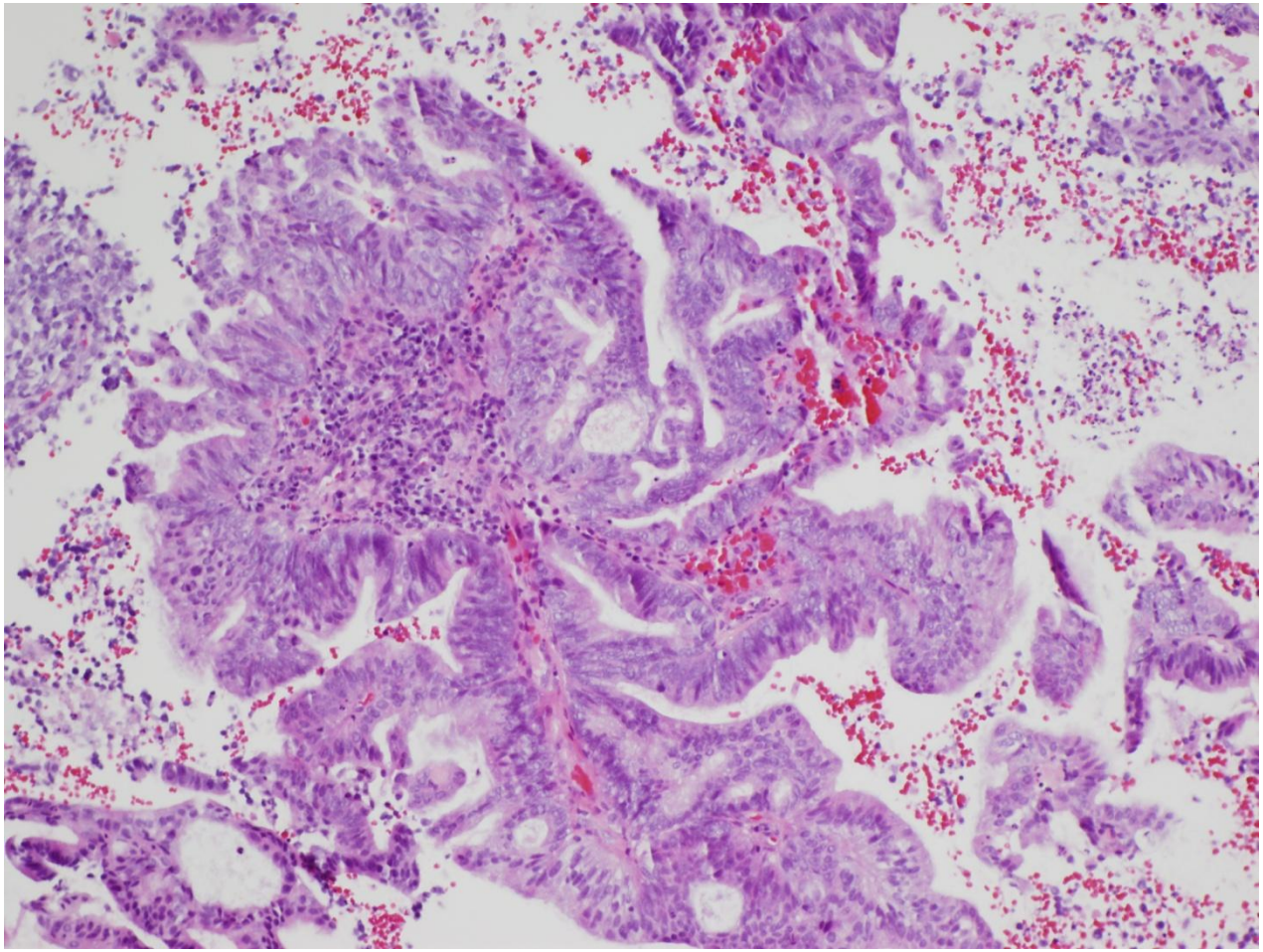

Dedifferentiated EC

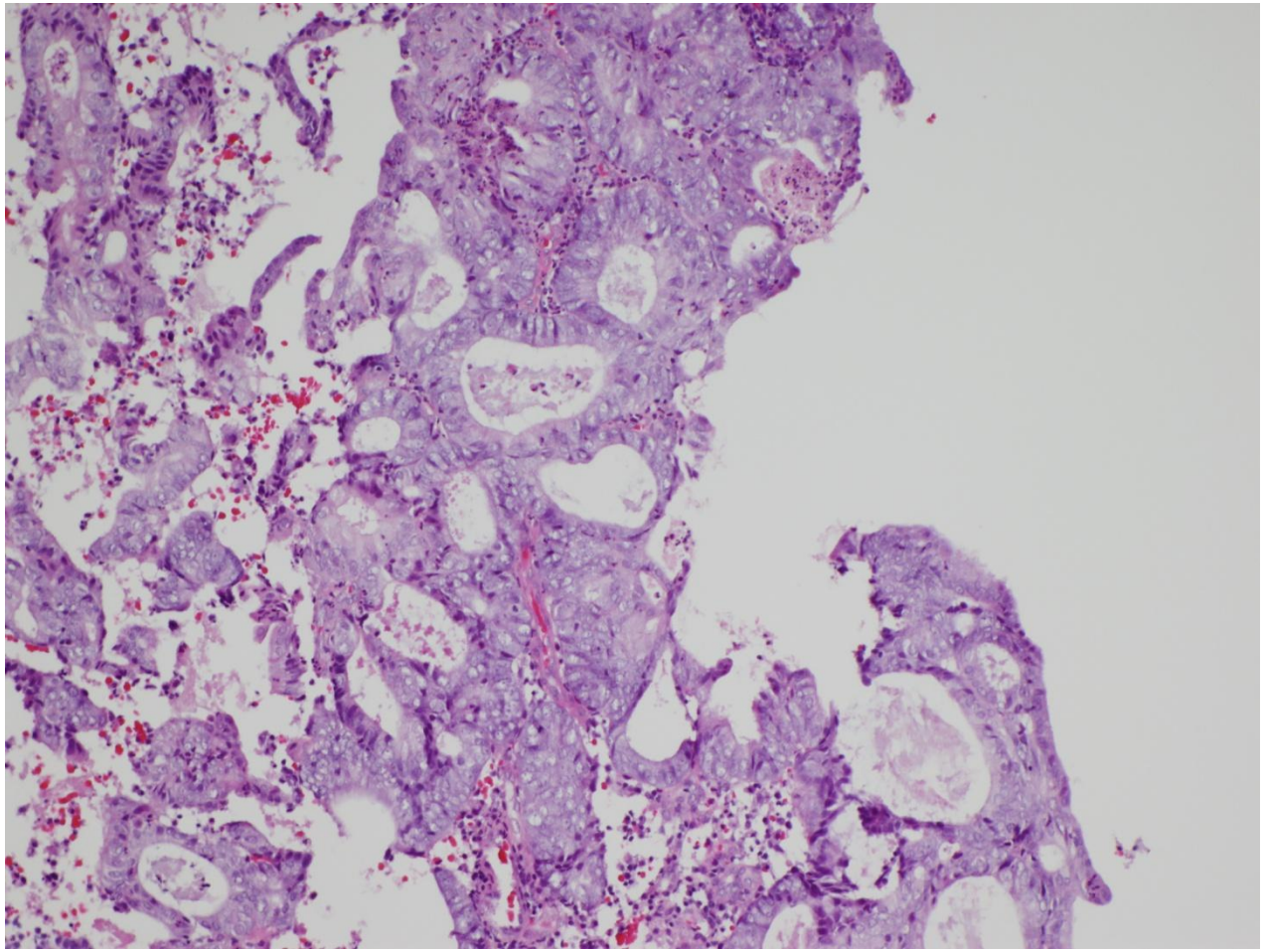

Dedifferentiated EC

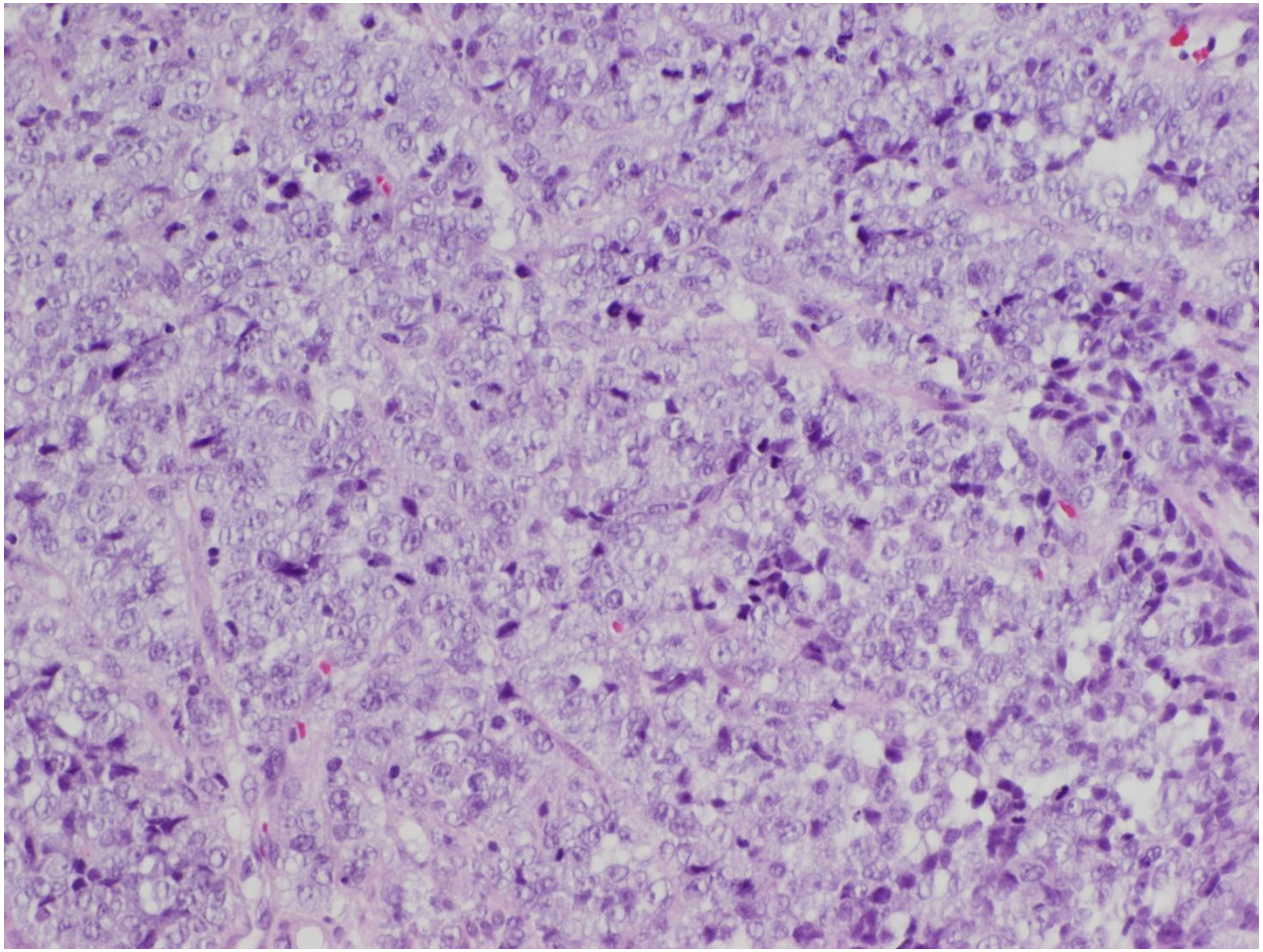

Dedifferentiated EC

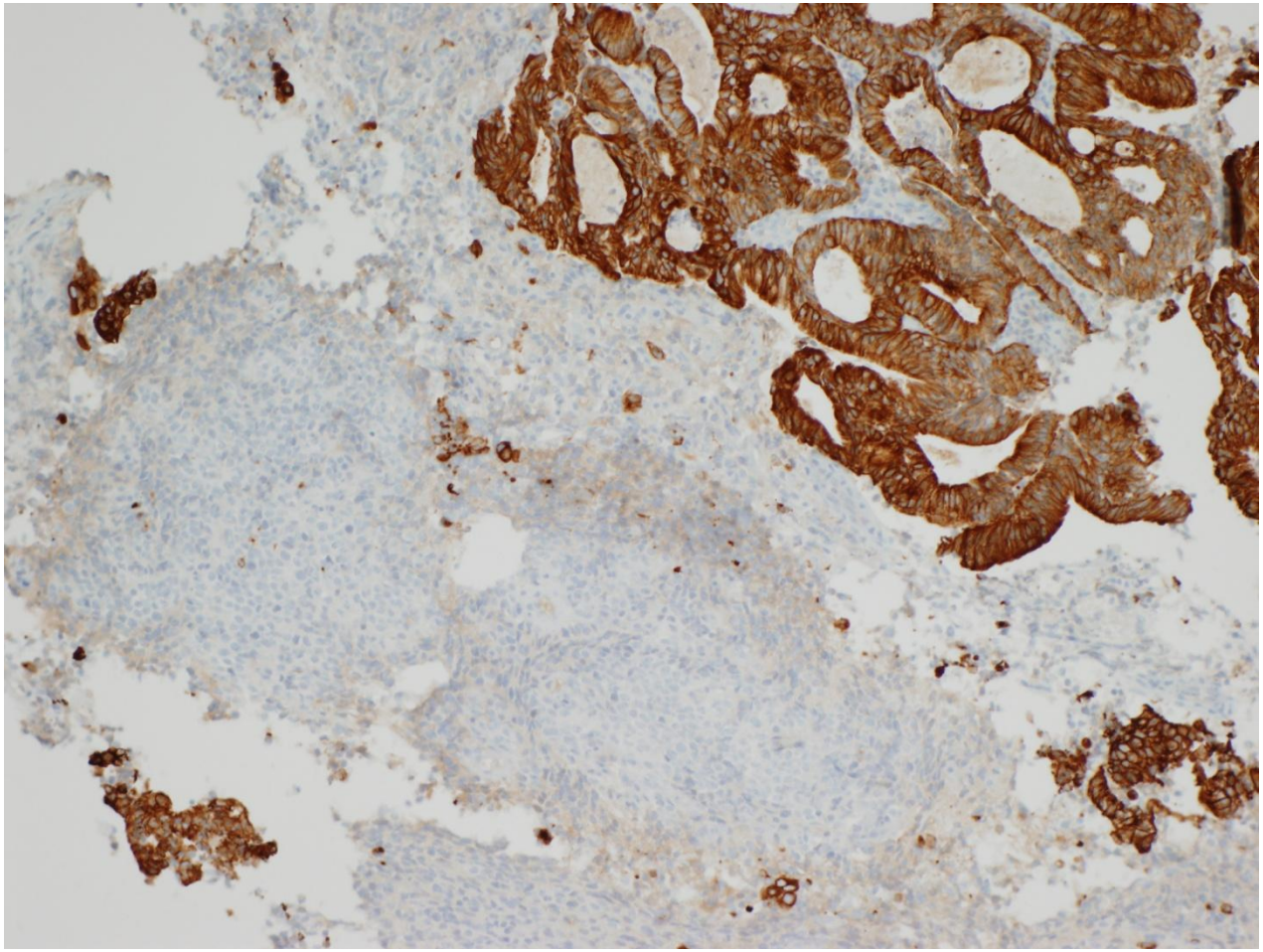

Monokeratin

Dedifferentiated EC

Corresponding hysterectomy

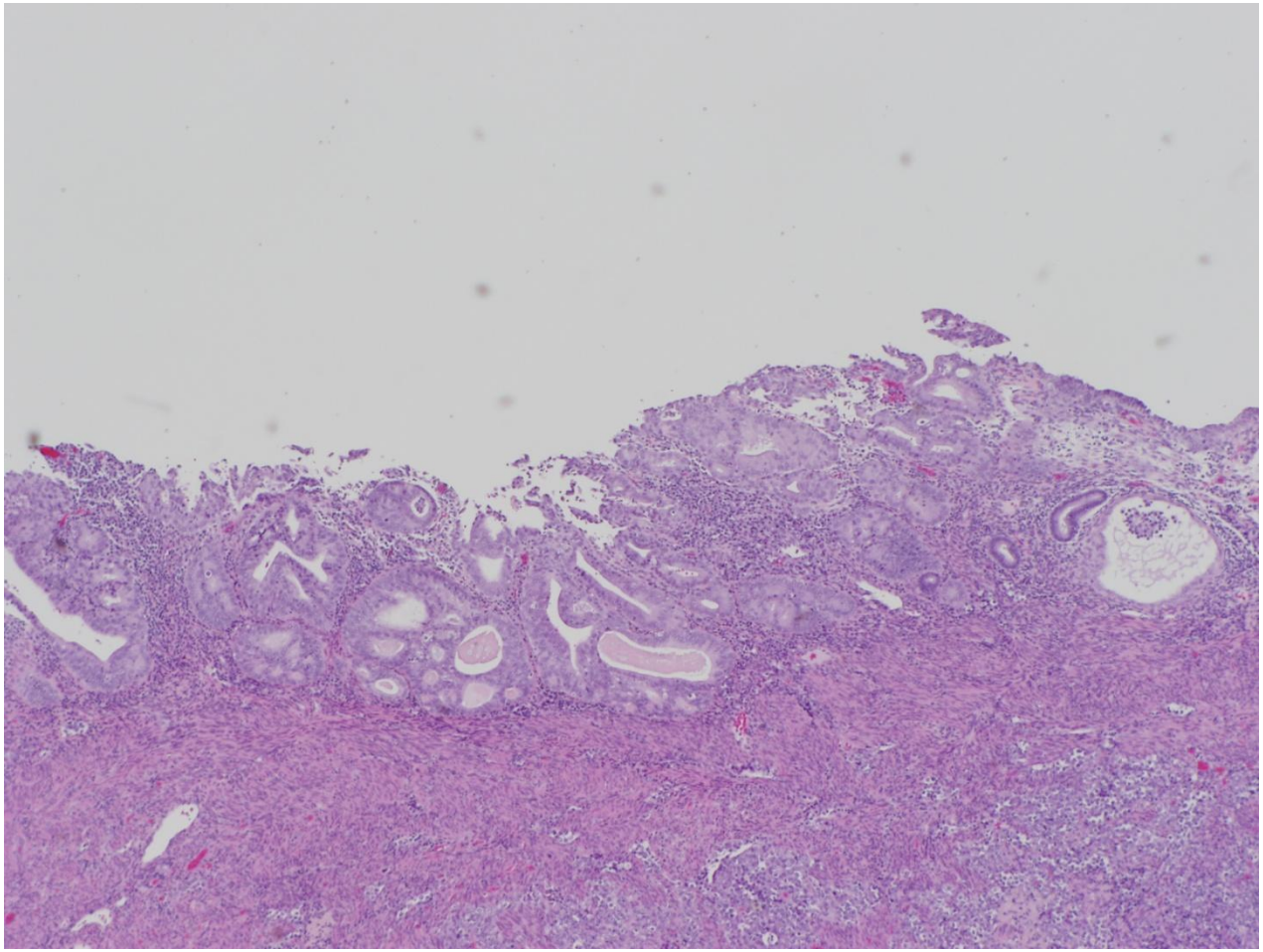

Evolving EEC undermined by UC

Dedifferentiated EC

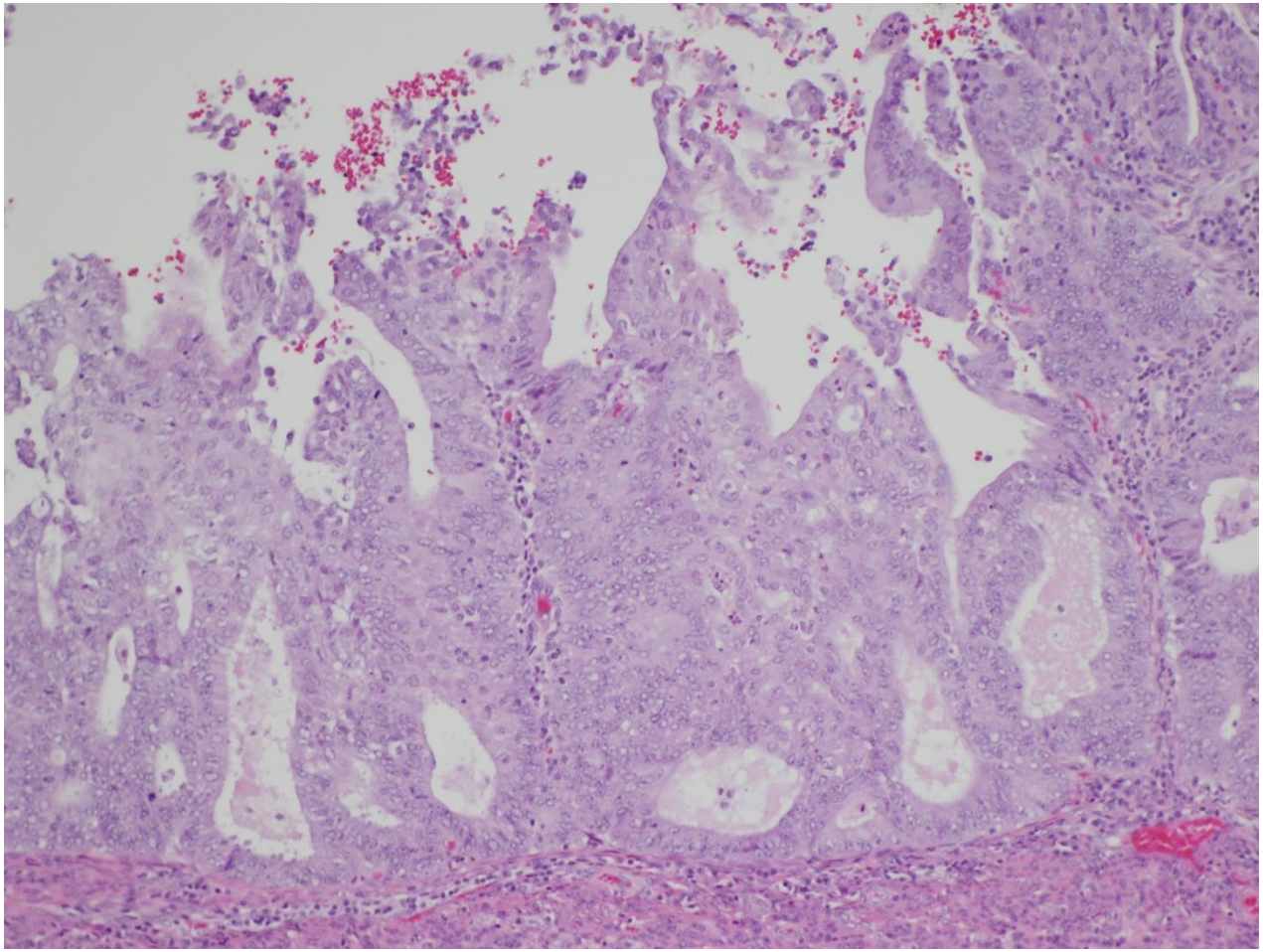

EEC component, FIGO grade 1

Dedifferentiated EC

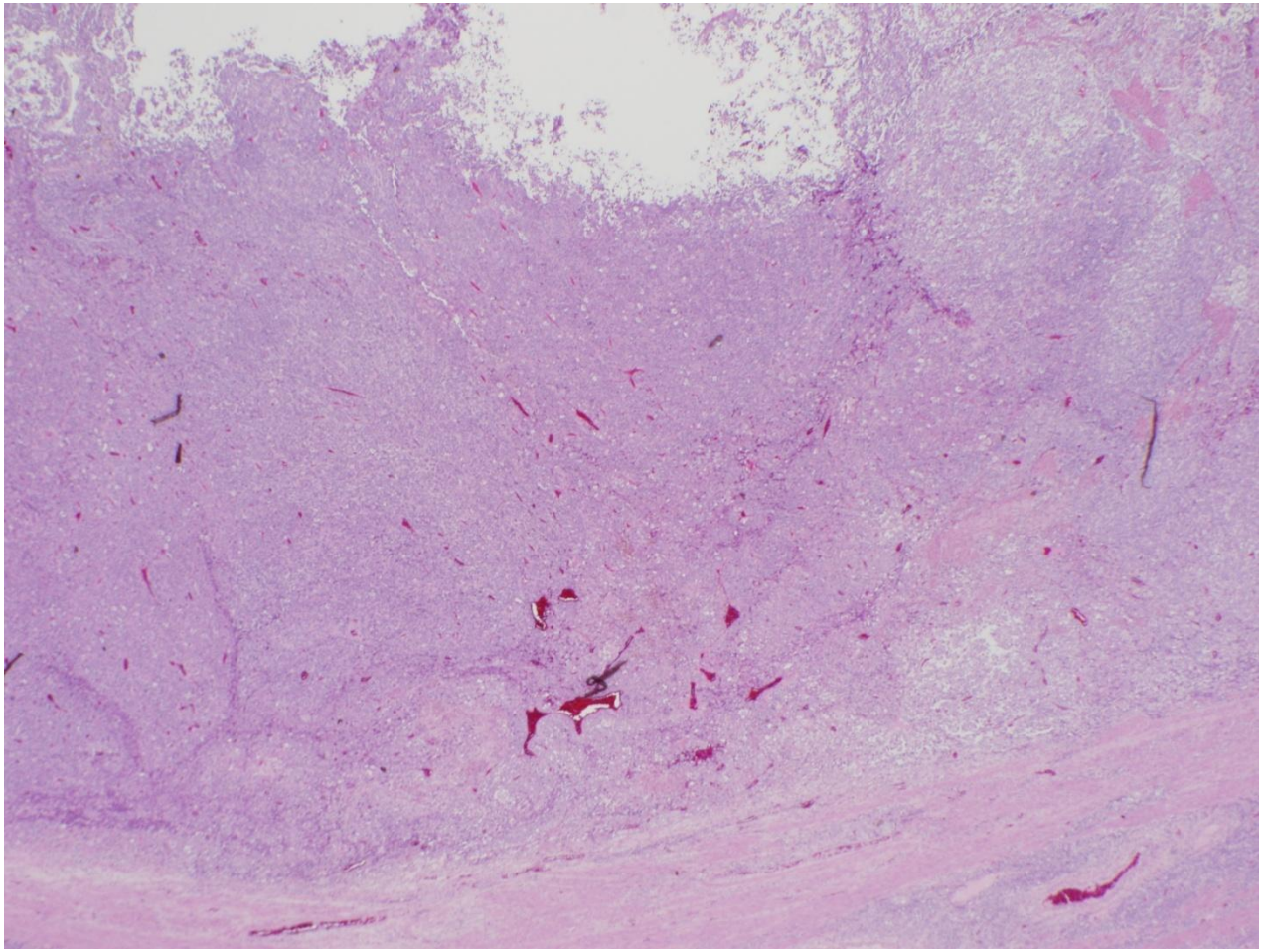

UC component

Dedifferentiated EC

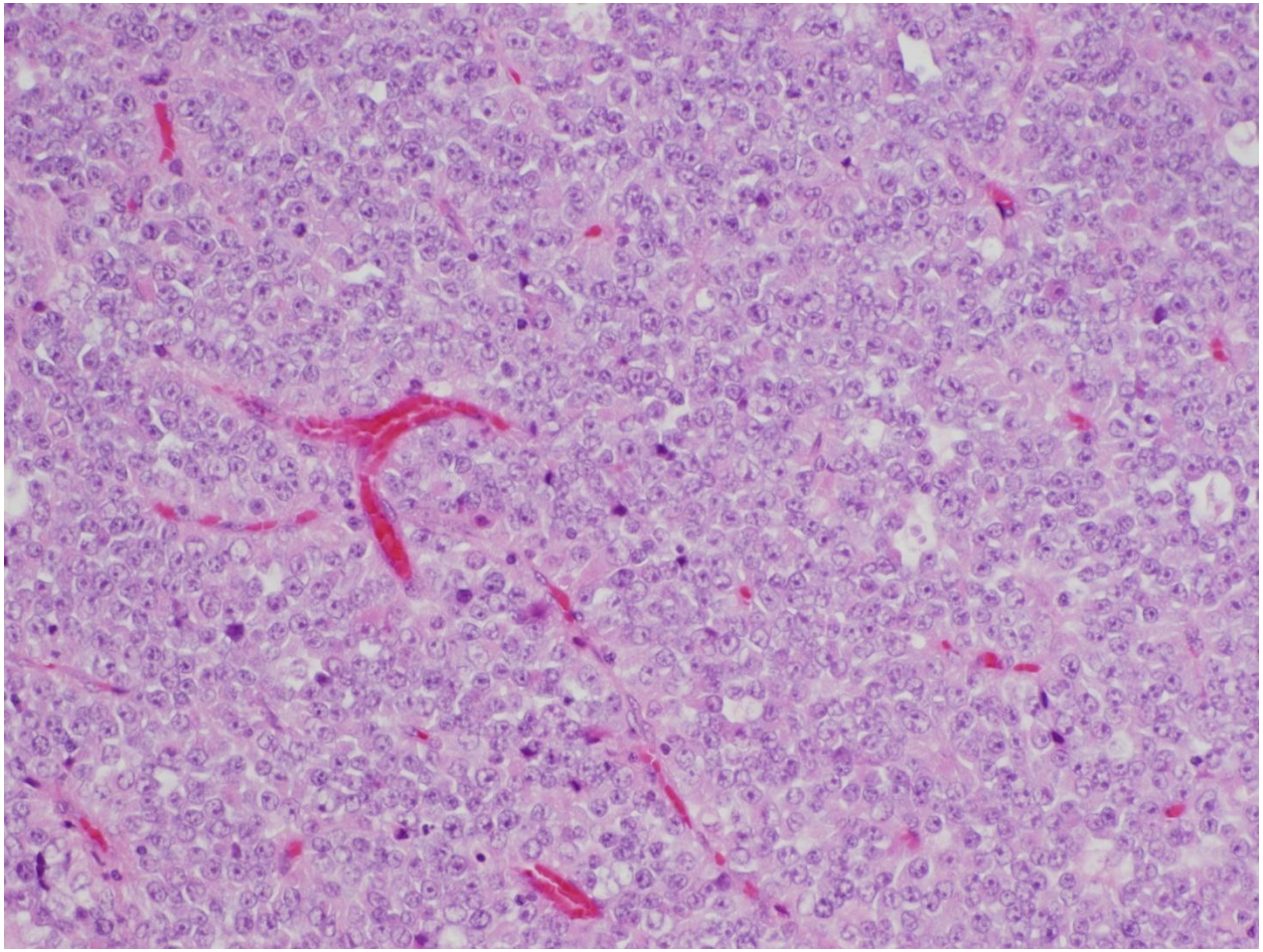

Sheets of monotonous cells

Dedifferentiated EC

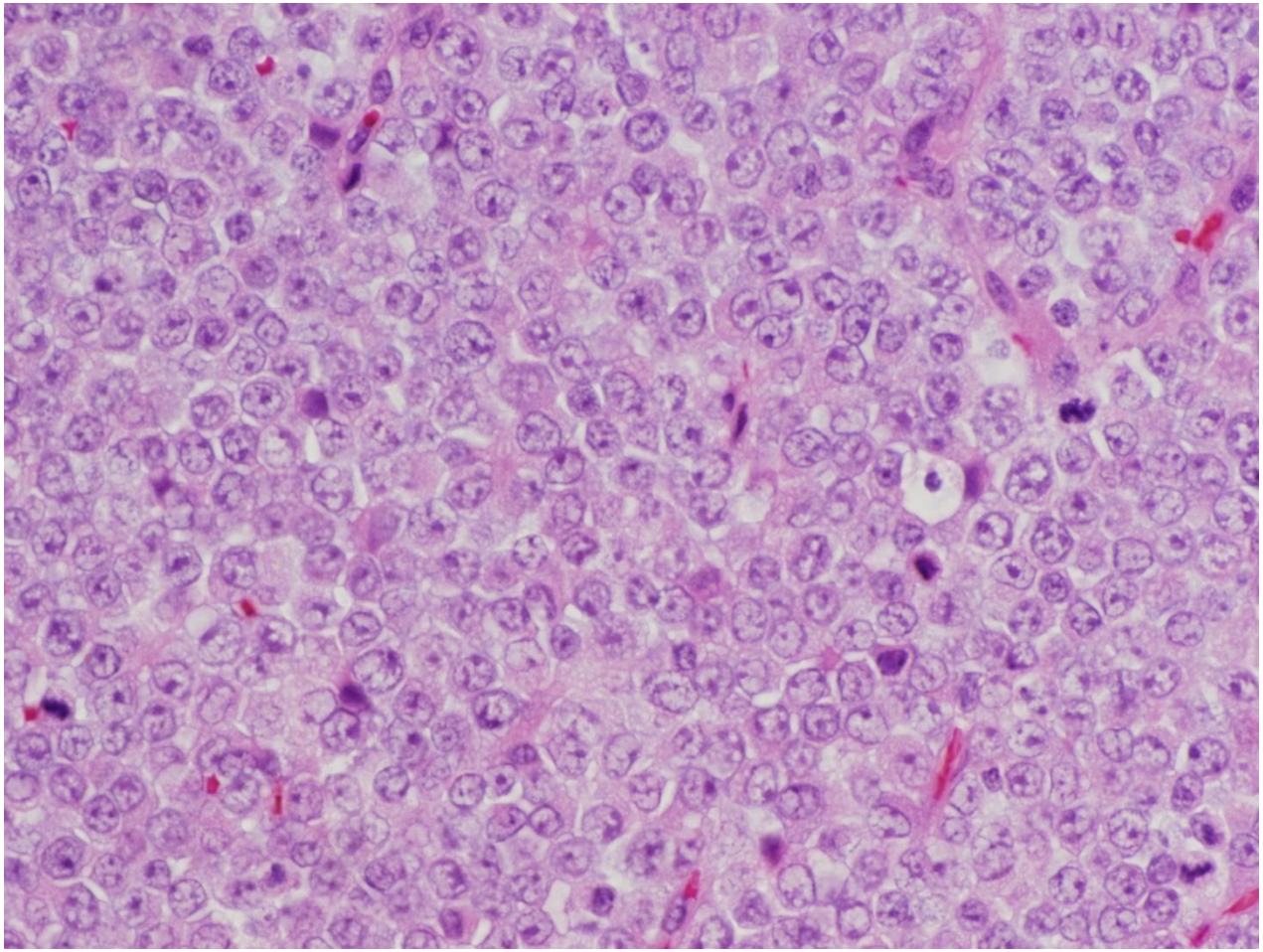

Histiocytoid, paucity of cytoplasm, vesicular nuclei, prominent nucleoli

Dedifferentiated EC

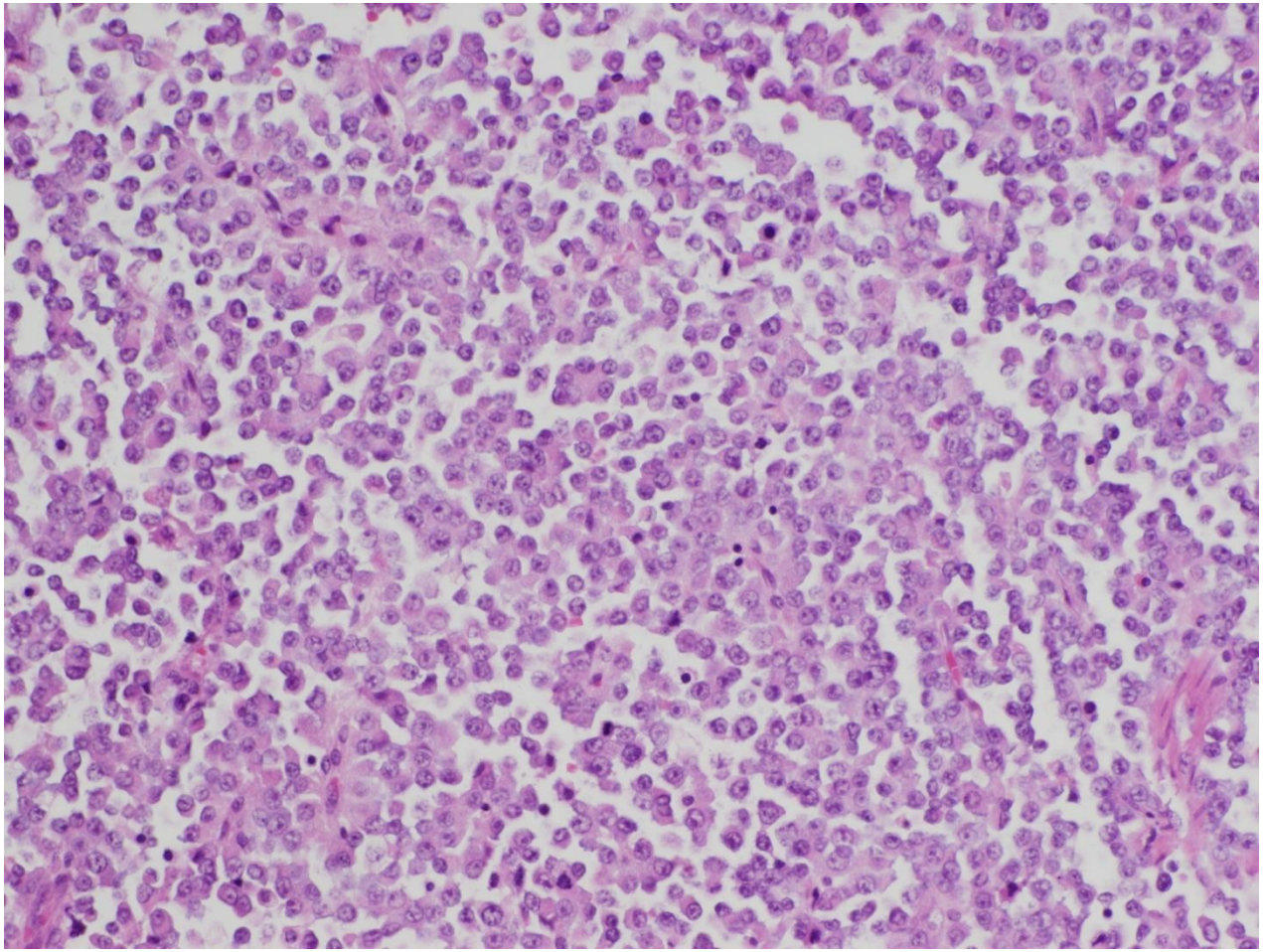

Dyshesive

Dedifferentiated EC

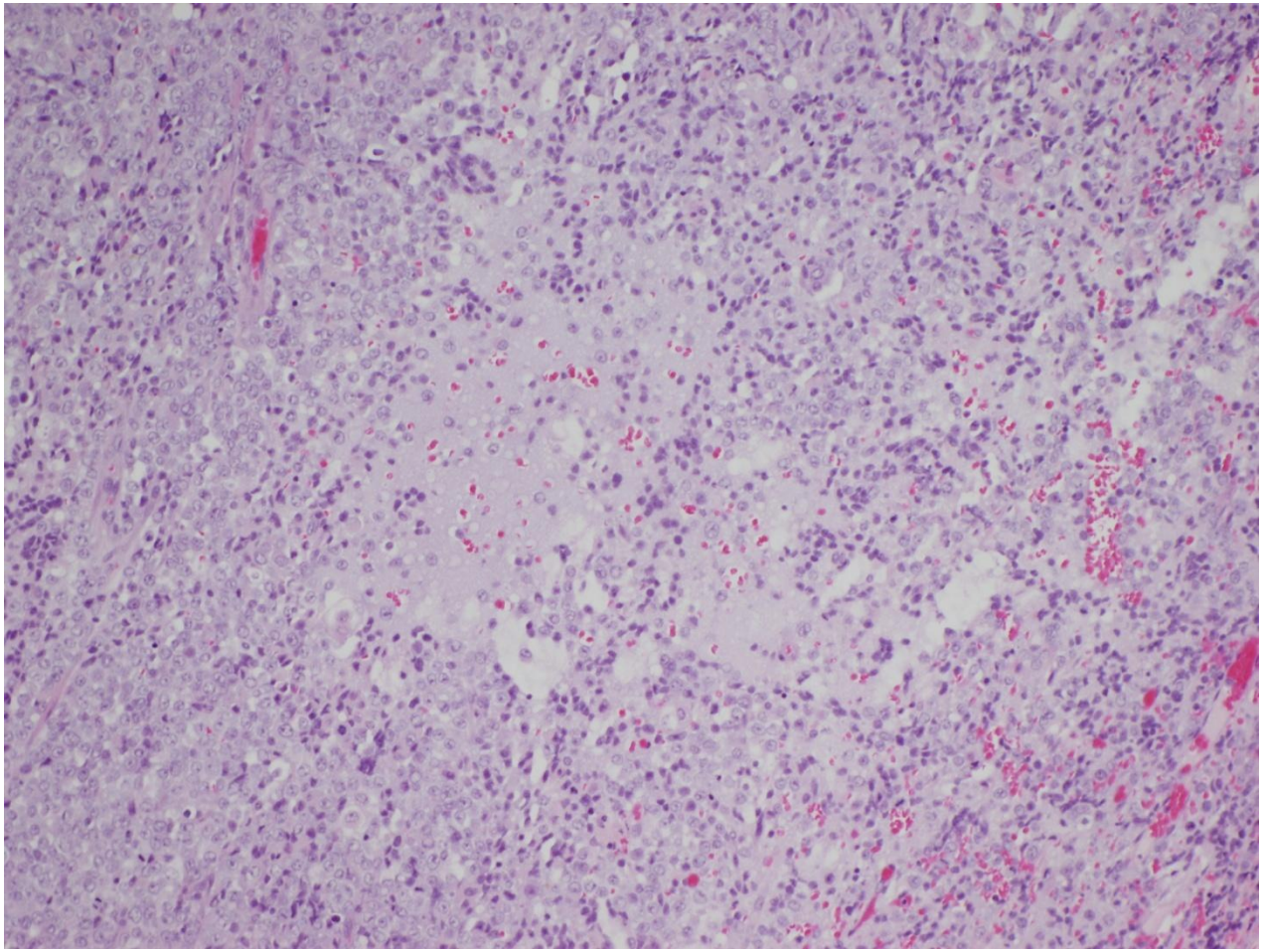

Myxoid zones

Dedifferentiated EC

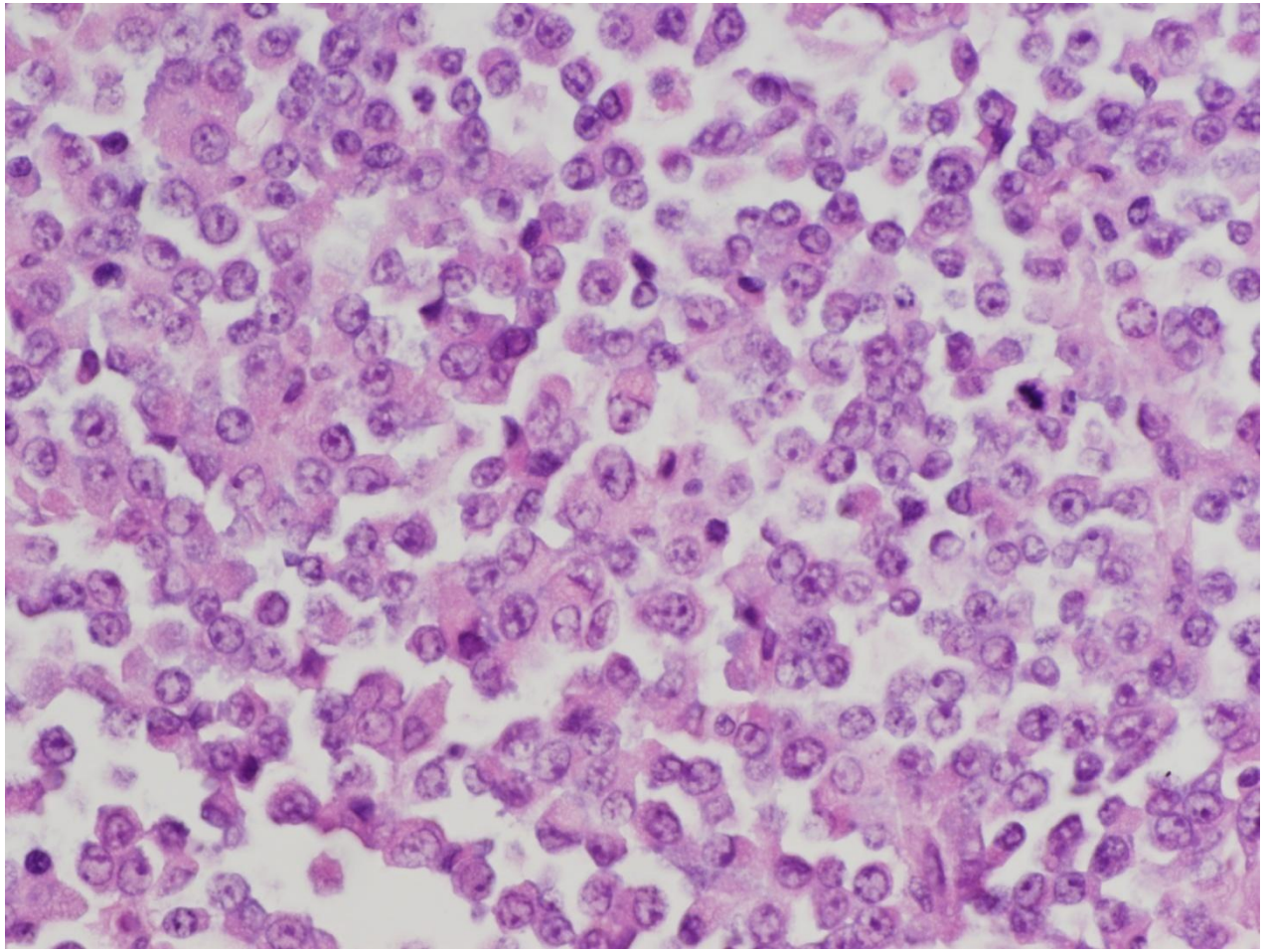

Rhabdoid forms

Dedifferentiated EC

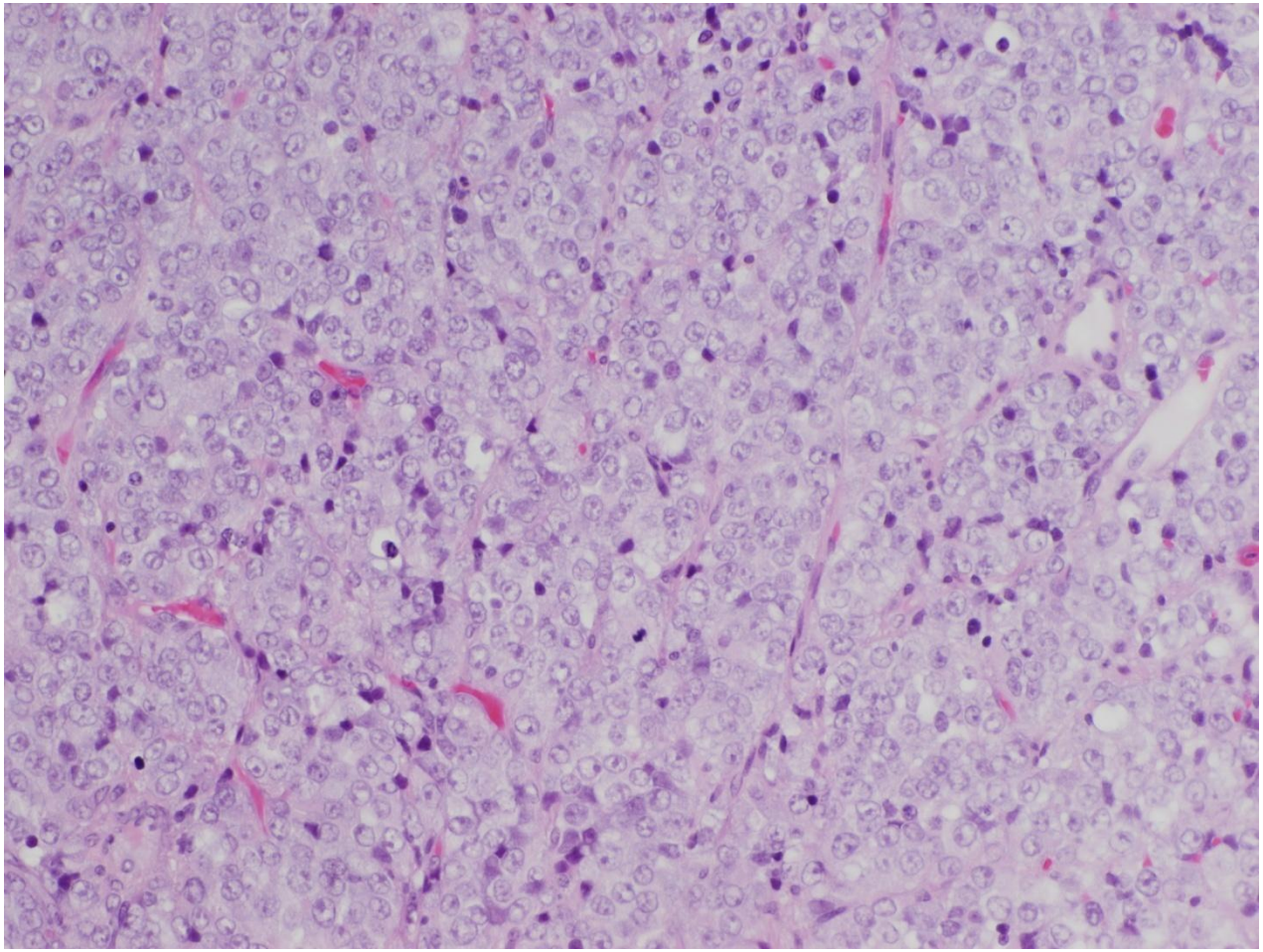

TILs

Dedifferentiated EC

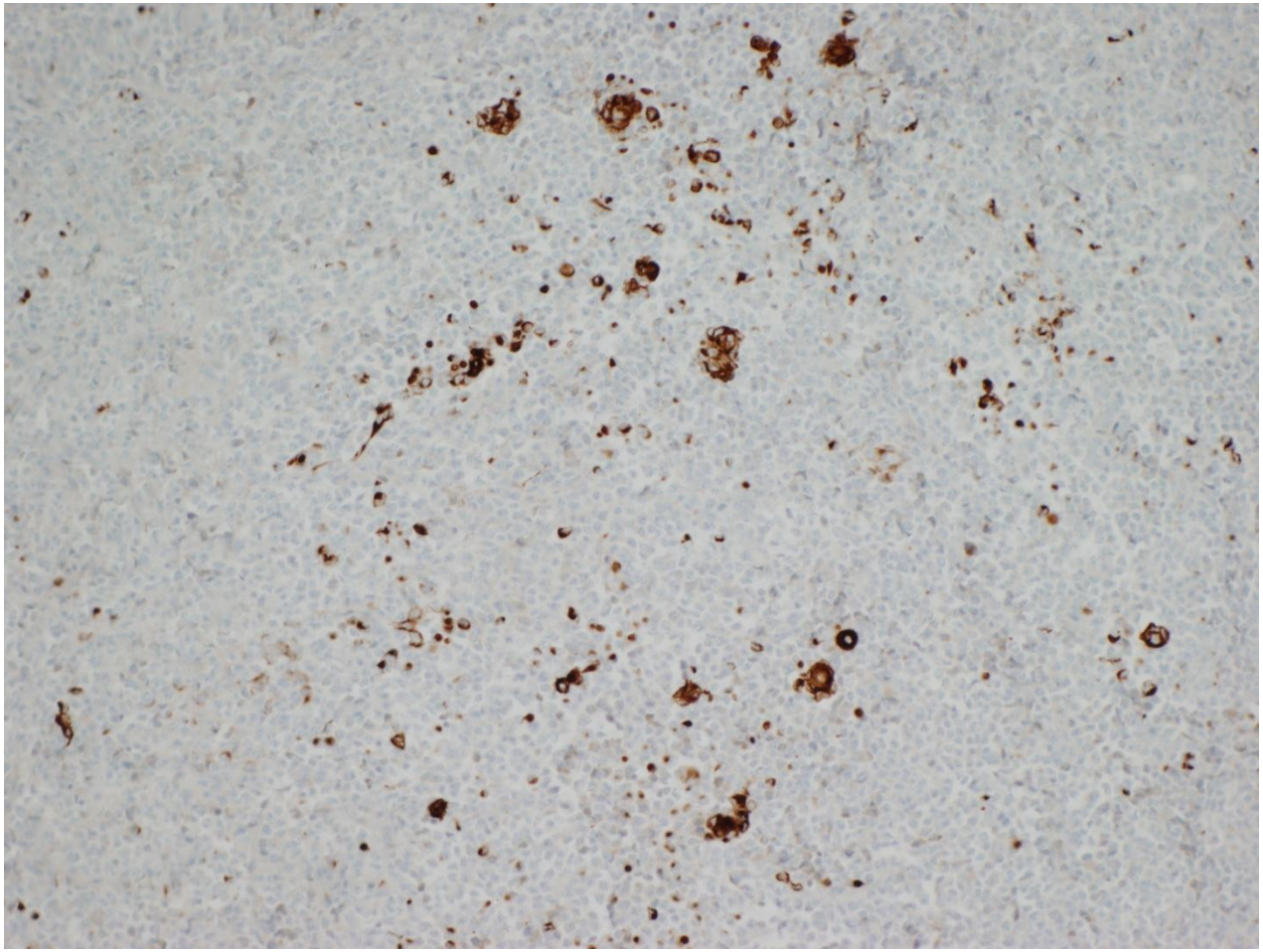

Monokeratin

Dedifferentiated EC

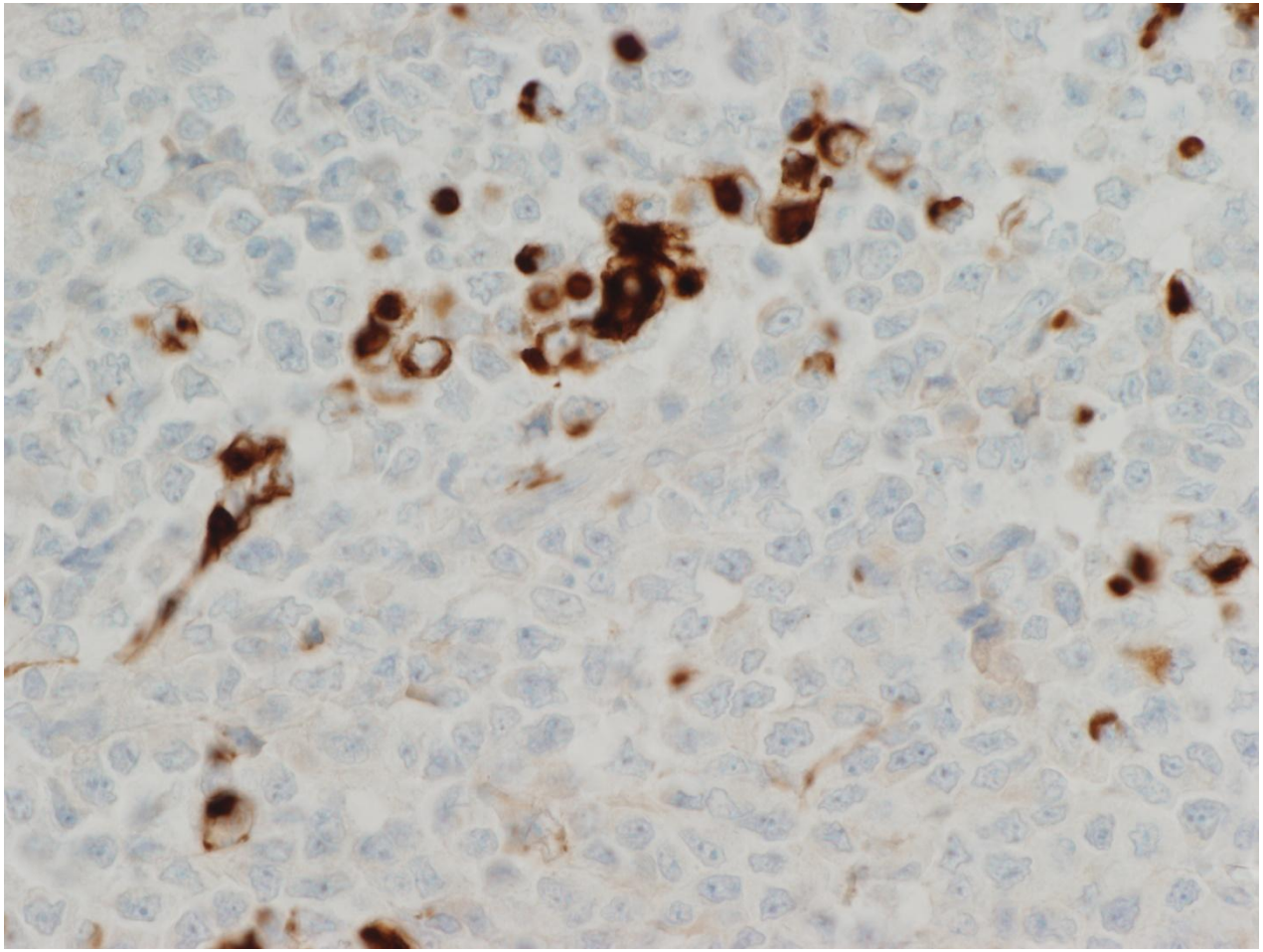

Monokeratin

Dedifferentiated EC

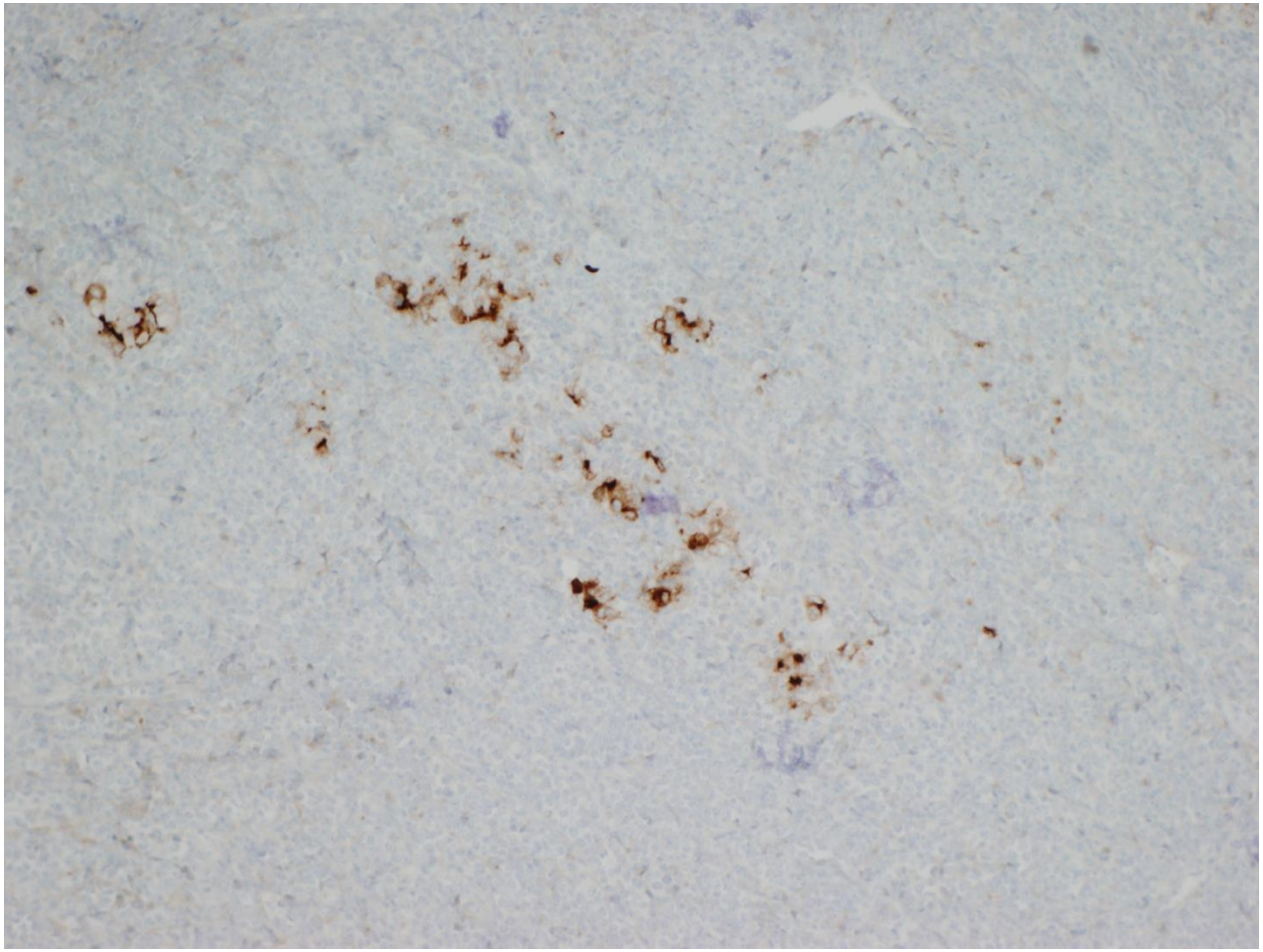

EMA

Dedifferentiated EC

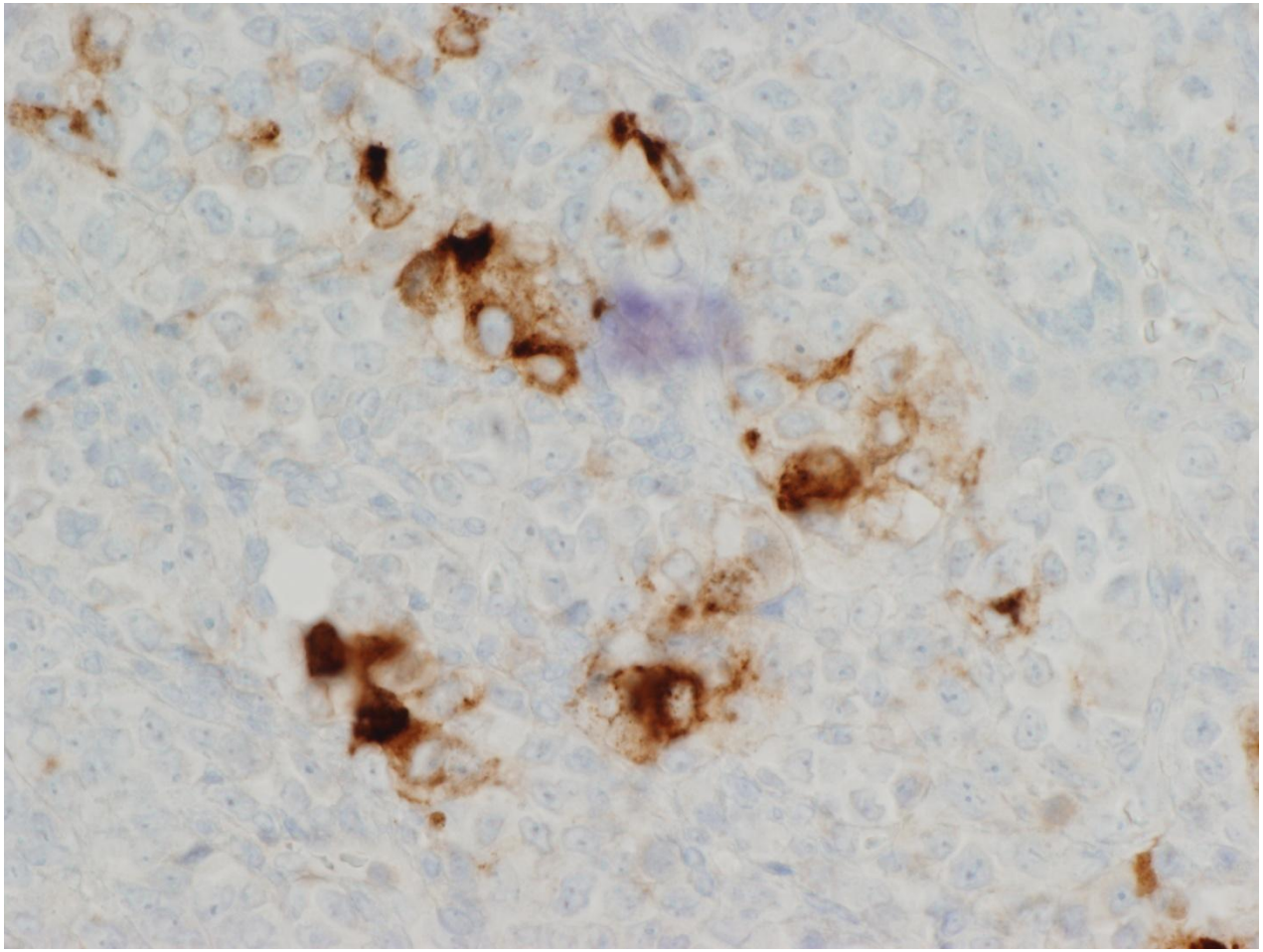

EMA

Dedifferentiated EC

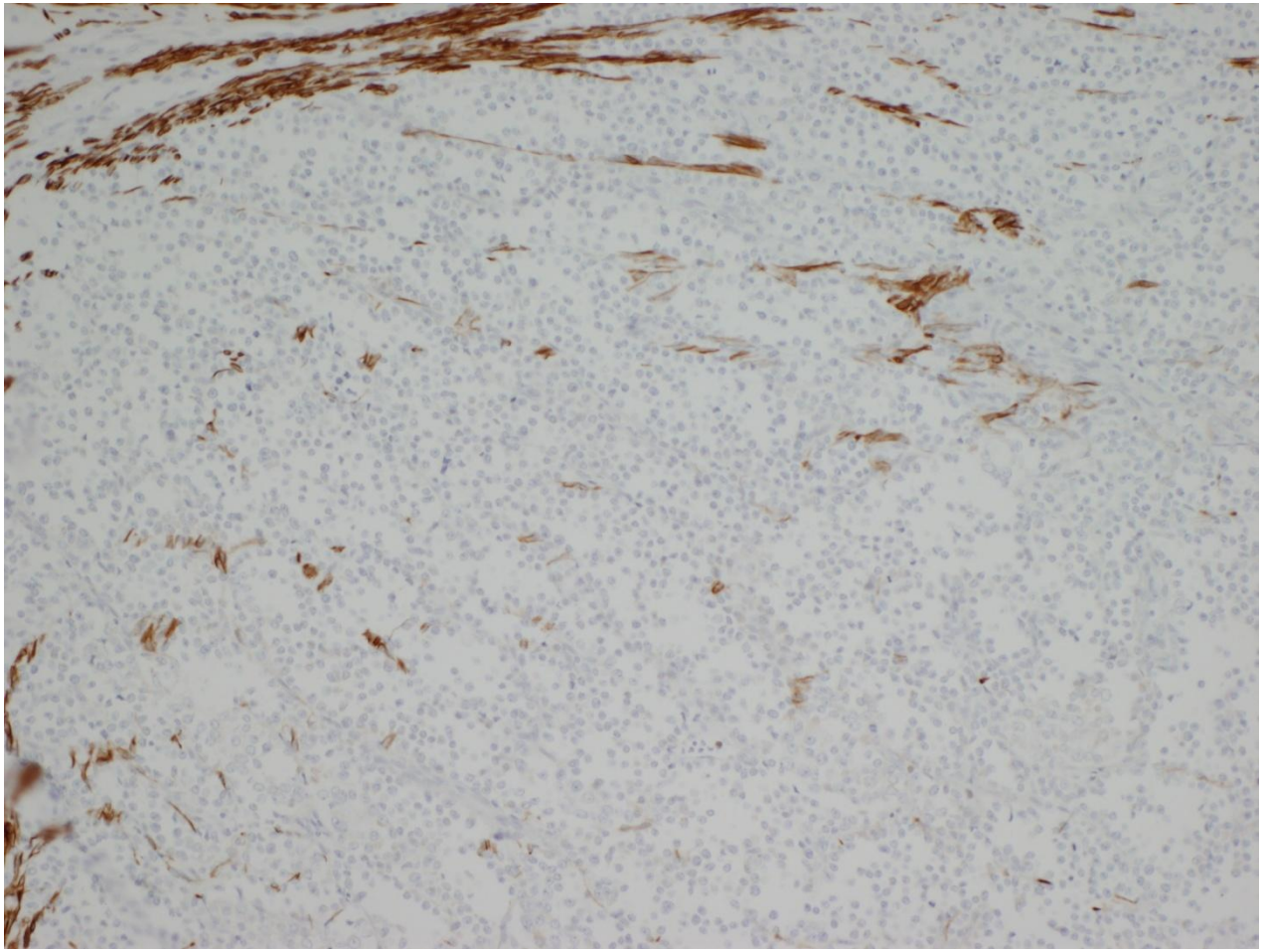

Desmin*

Dedifferentiated EC

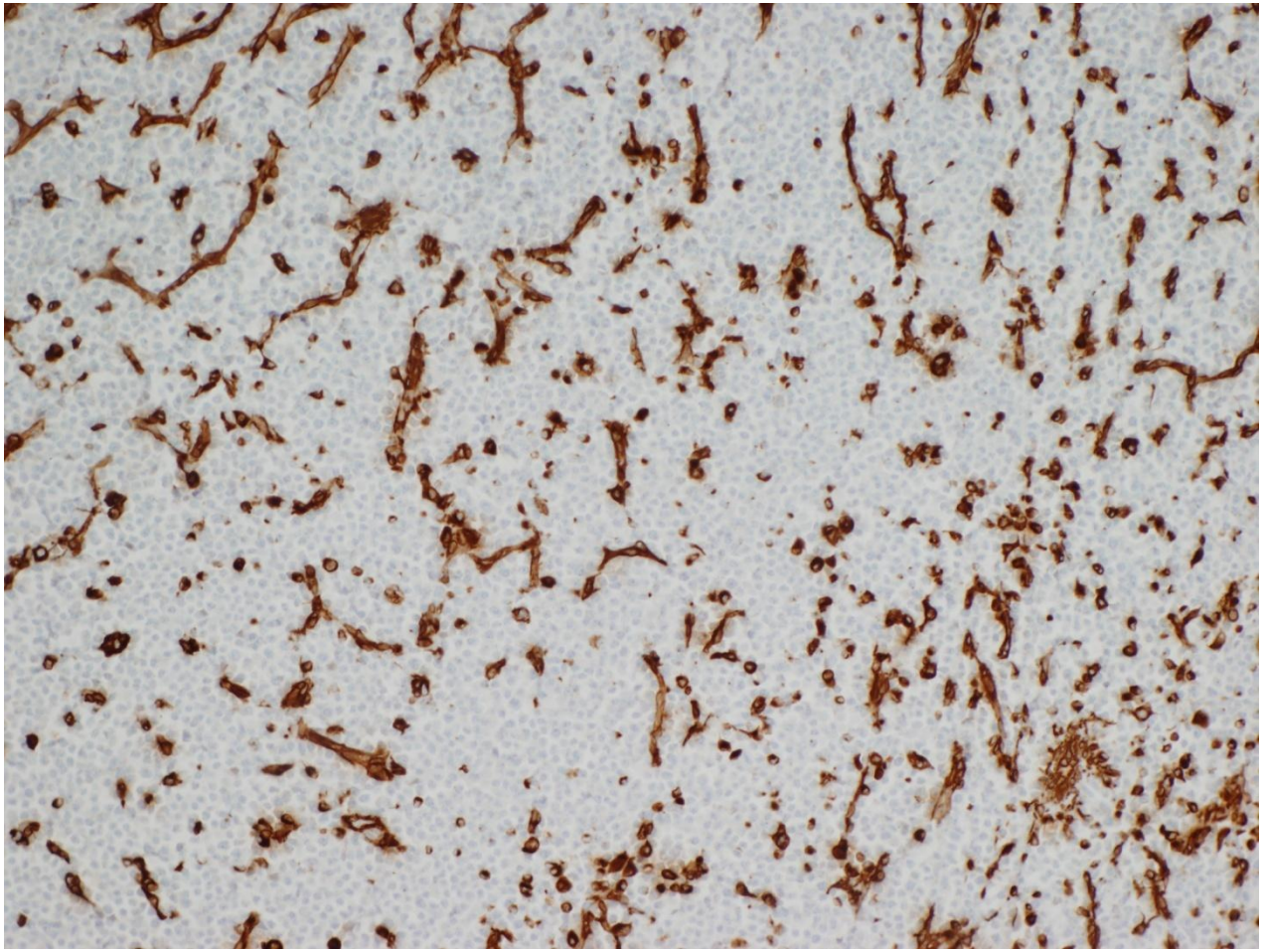

Vimentin

Dedifferentiated EC

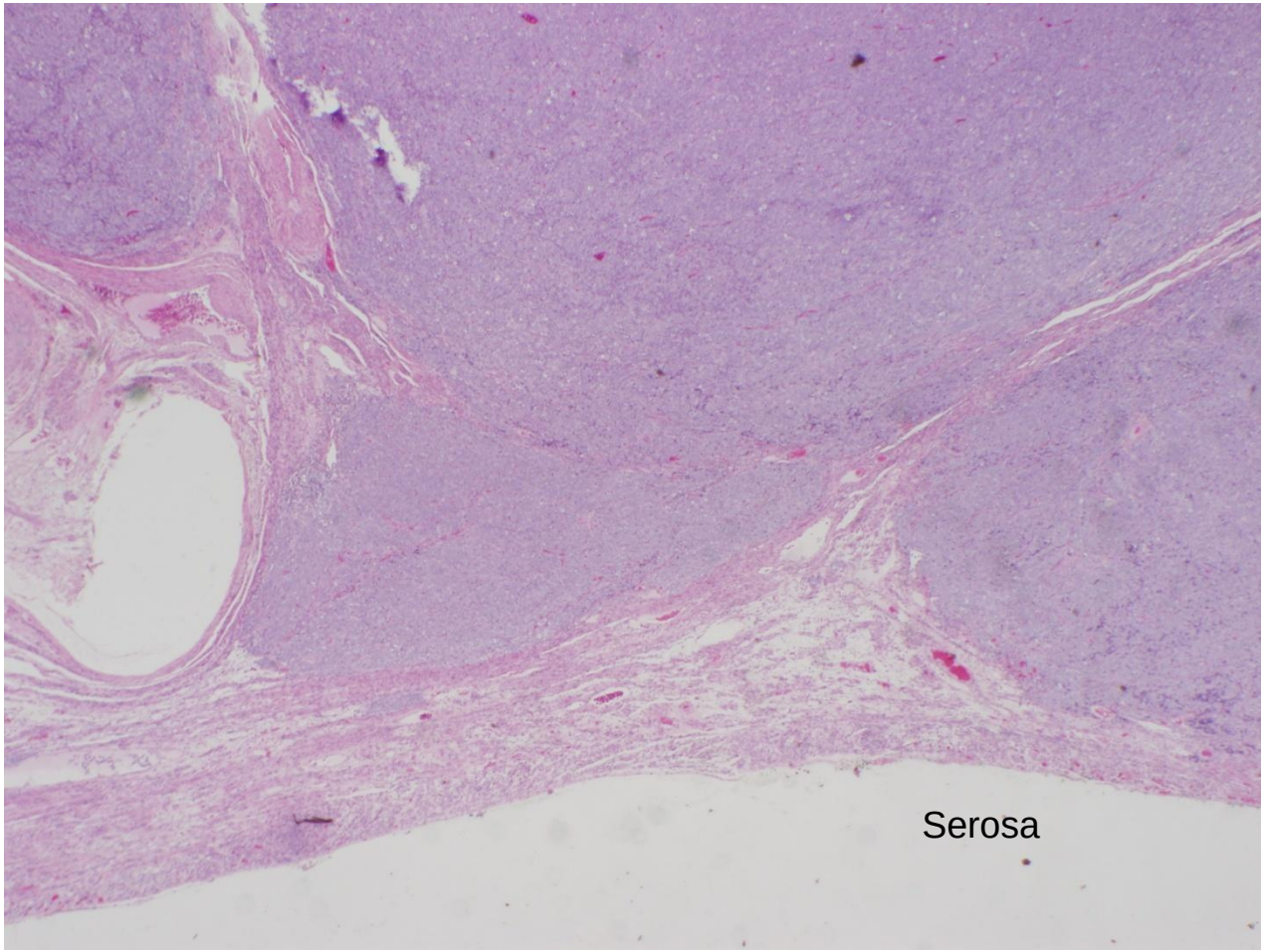

Dedifferentiated EC

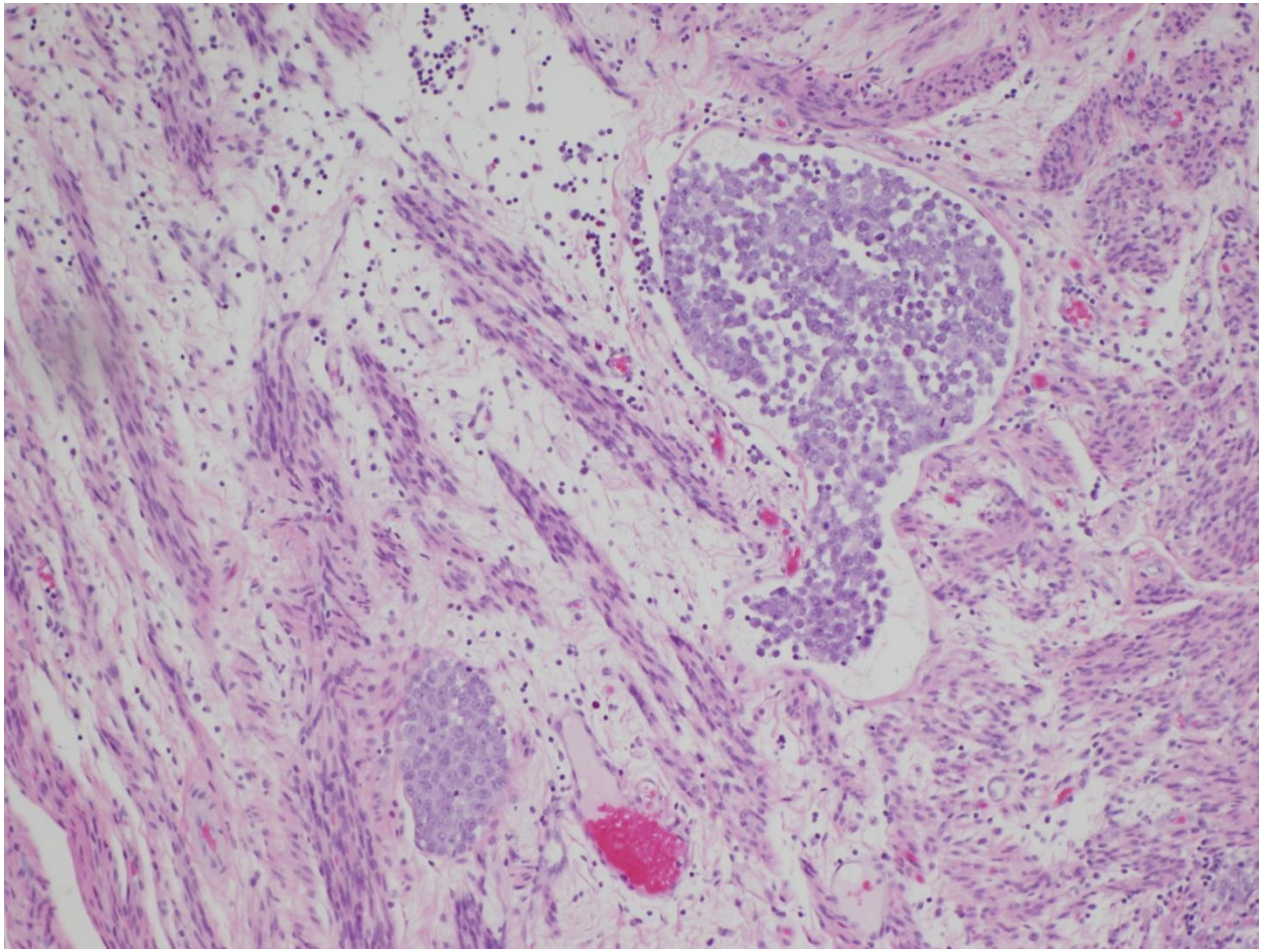

LVI

The mets in dediff EC are typically the UC component

MMMT

- Malignant Mullerian Mixed Tumor / Carcinosarcoma
- Monoclonal, thought to be derived from Ca
- Similar RF as EEC
- 40% extrauterine at presentation
- Classically is a fleshy polypoid mass
- DDX:
  - High grade EEC (sarcomatoid)
  - Dedifferentiated EC
  - EC with SCE / heterologous elements, adenosarcoma, UES / heterologous sarcomas

MMMT

- Carcinomatous and sarcomatous elements that are intimately admixed (but demarcated)
- Carcinoma is high grade (EEC, USC, NOS)
- Sarcoma is high grade
  - Homologous or heterologous
  - Hyaline globules
- Metastases are typically carcinomatous
- Both components often p16/p53 +
- ER is typically negative

MMMT

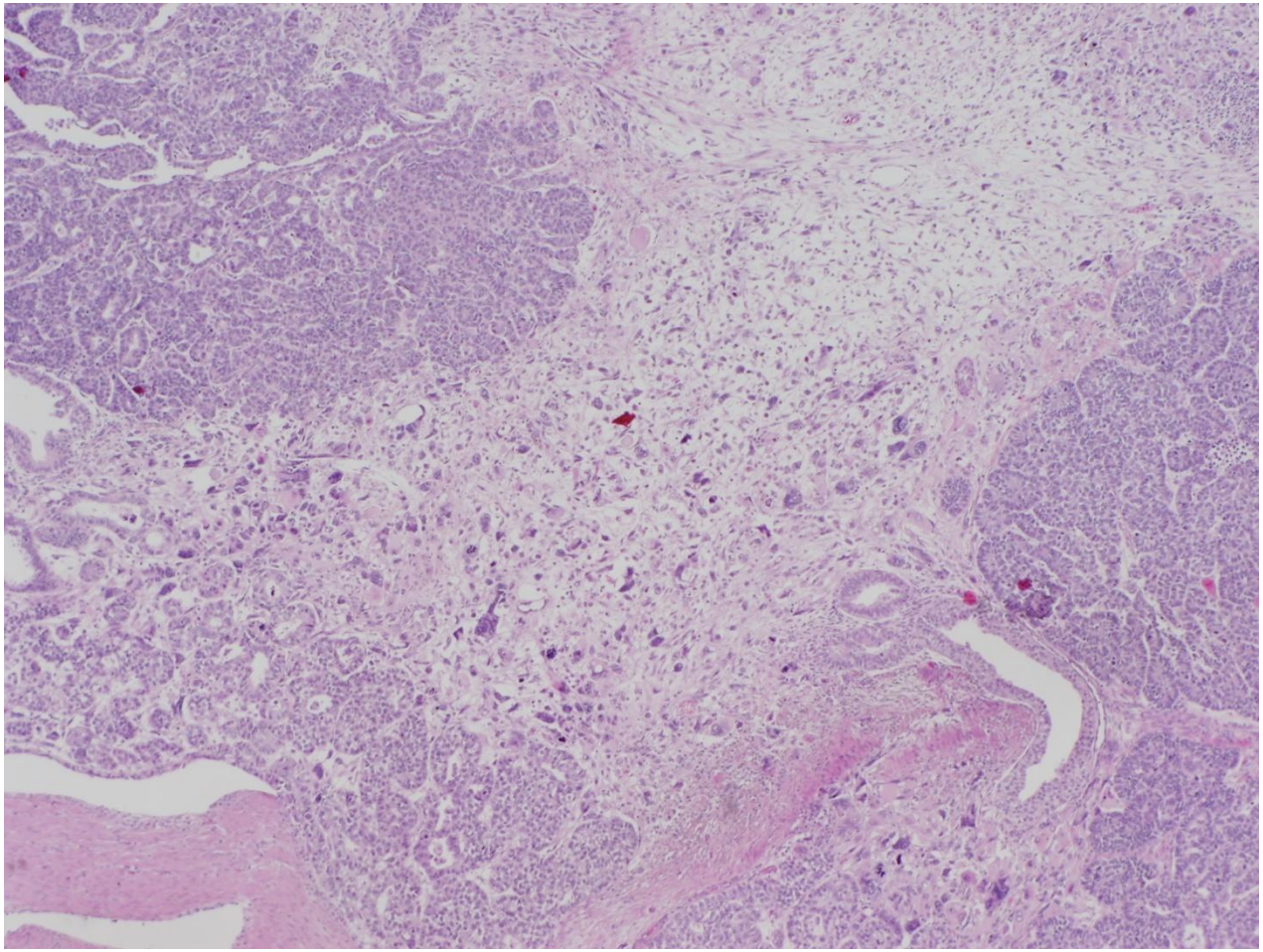

Biphasic, intermingled but demarcated components

MMMT

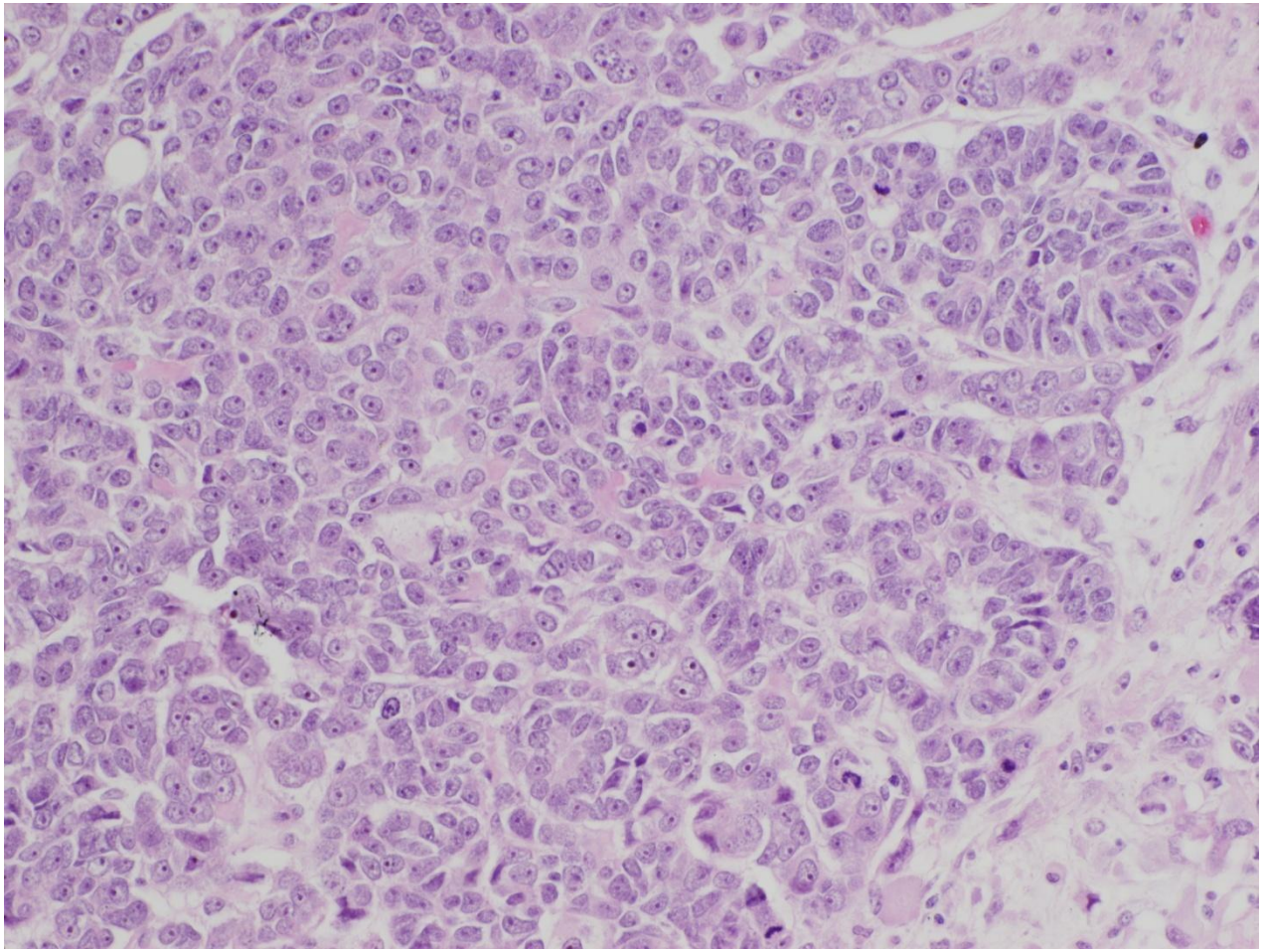

HG carcinoma

MMMT

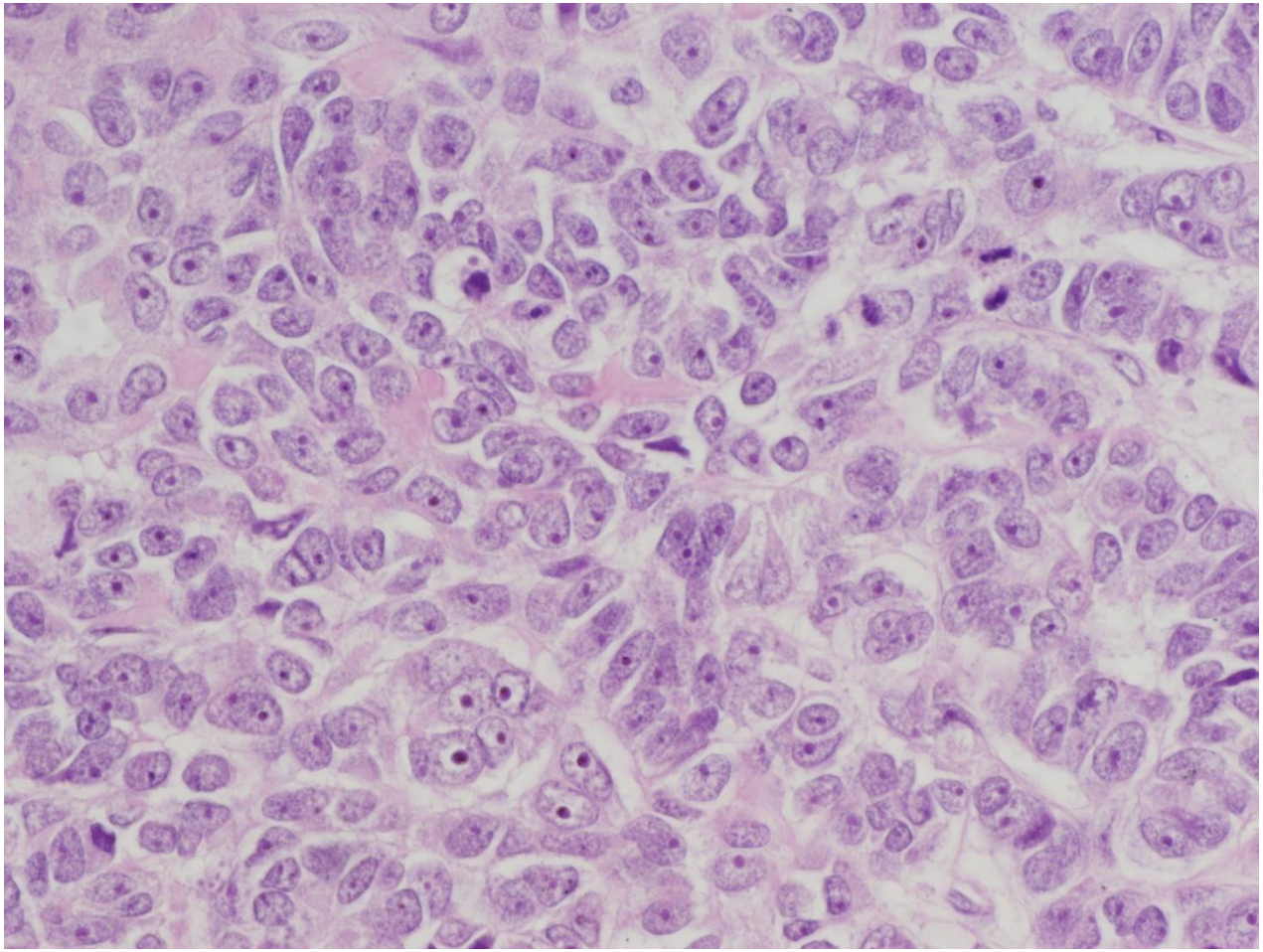

HG carcinoma

MMMT

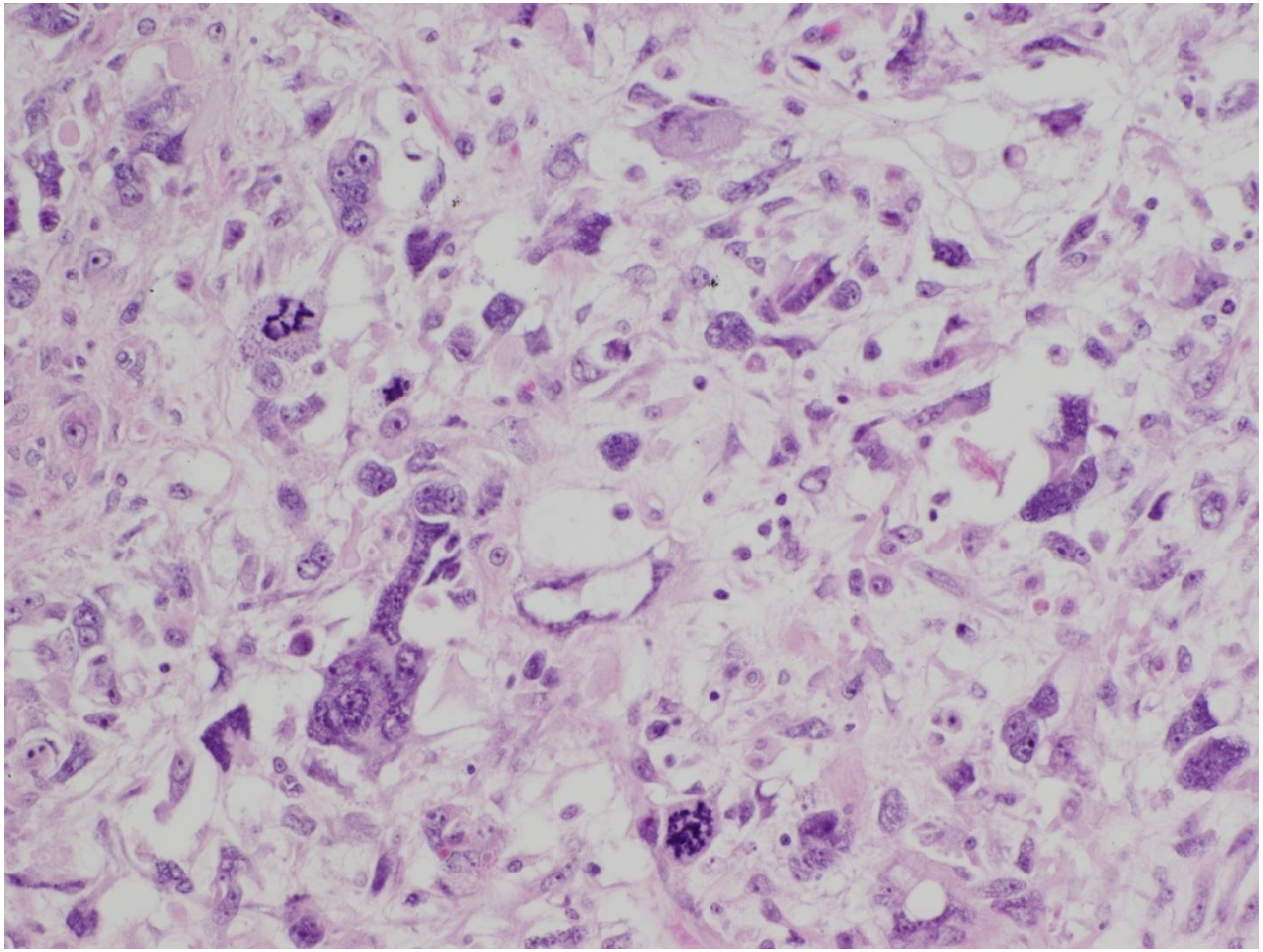

HG sarcoma

MMMT

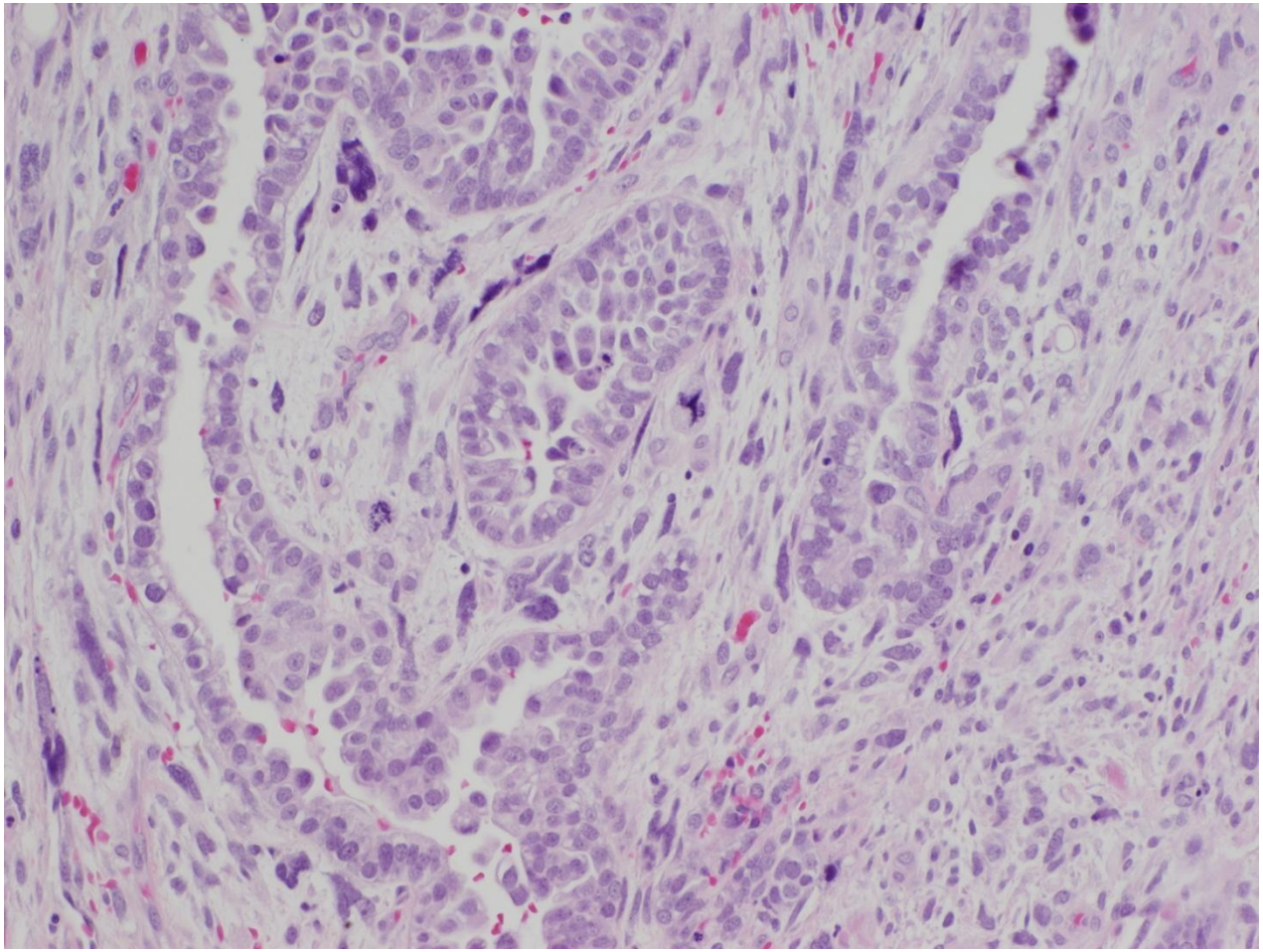

MMMT

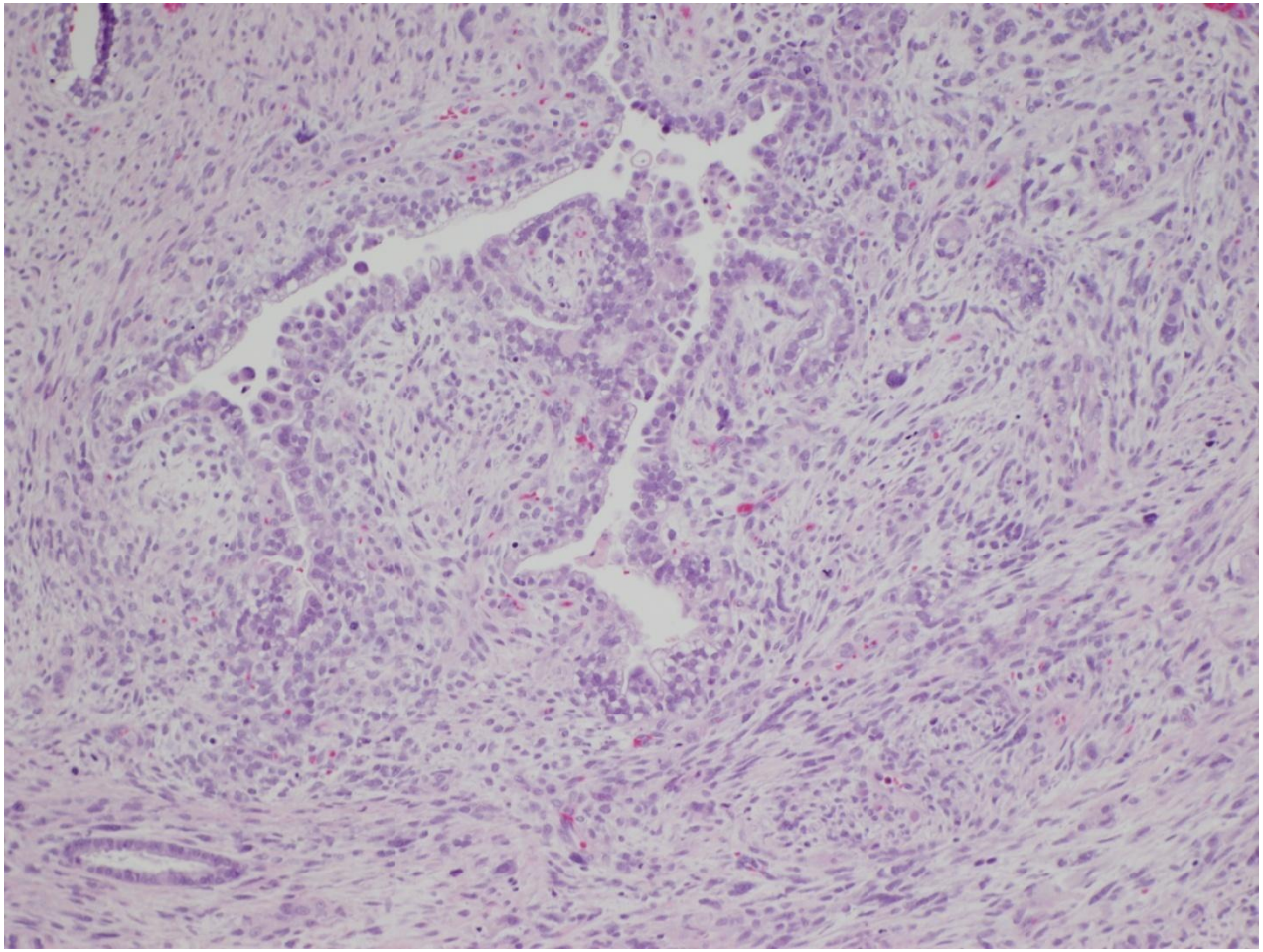

MMMT

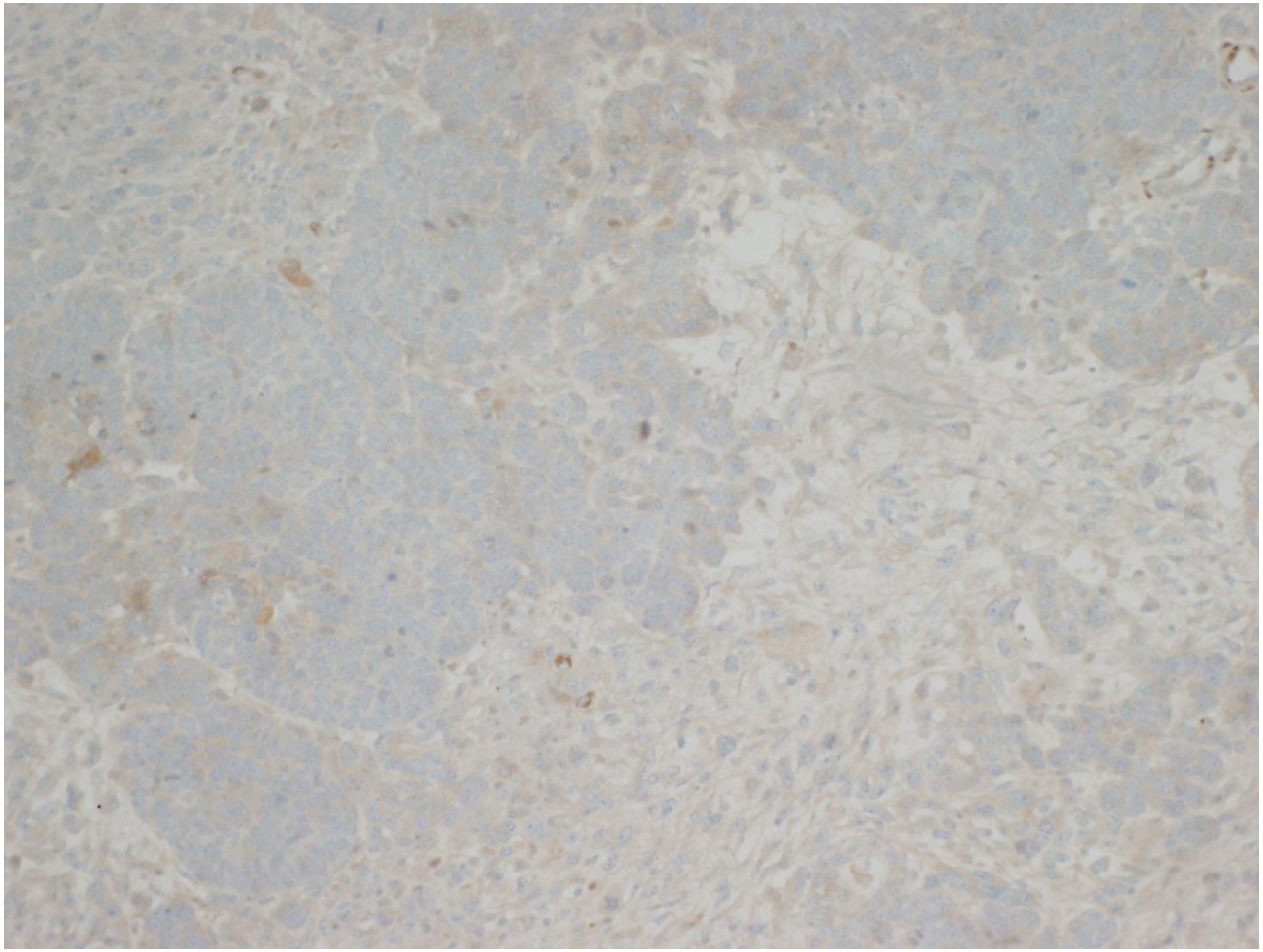

ER

MMMT

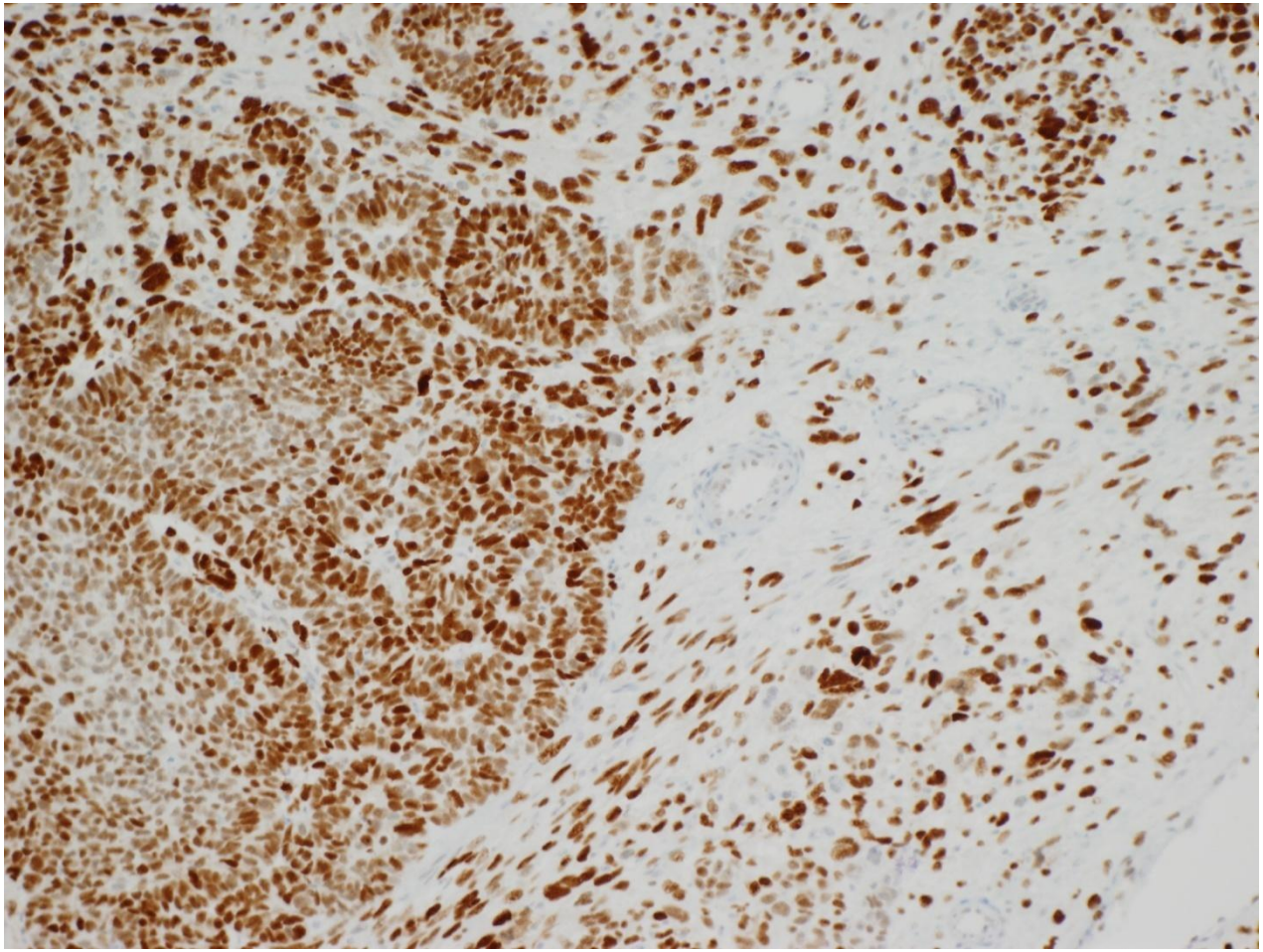

p53

Dediff. EC vs. FIGO grade 3 EEC

Dedifferentiated EC

- Biphasic look, demarcated components
- UC areas devoid of glands, dyshesive, lymphoma-like, cytology differs from EEC
- Rhabdoid cells, myxoid stroma, TILs
- CK/EMA neg/focal in UC

FIGO 3 EEC

- Merging of gland rich and gland poor zones
- Sheet-like areas punctuated by glands, maintain cytology similar to glandular areas
- Not associated
- CK/EMA+

Dediff. EC vs. MMMT

Both have biphasic appearance with demarcated components

Dedifferentiated EC

- UC associated with background EEC (gr 1>2)
- No sarcomatous component or heterologous elements
- UC is monotonous

- EEC regions CK+/ER+/p53-/p16-
- UC regions CK-/focal intense
- Mets: UC

MMMT

- Sarcoma associated with background HG Ca
- Definitionally a sarcomatous component +/- heterologous
- Sarcoma typically pleomorphic
- HG Ca CK+/ER-/p53+/p16+
- Sarcoma CK-/p53+/p16+
- Mets: HG Ca

EEC with mucinous component

- EEC with mucinous differentiation / Mucinous carcinoma

- *Microglandular EEC (MGH-like)*

- DDx:
  - Endocervical adenocarcinoma
  - *Microglandular hyperplasia (MGH)*

EEC with mucinous differentiation

- **< 10% mucinous – EEC with mucinous differentiation**
- > 10% mucinous – Mixed EEC – Mucinous
- > 90% mucinous (or “mostly” mucinous) – Mucinous Carcinoma
- Similar presentation to conventional EEC
  - Strong association with progestins, tamoxifen

EEC with mucinous differentiation

- Endocervical-type mucinous cells, admixed oxyphilic cells
- Glandular, cribriform, villoglandular, villous
- Neutrophils
- **MGH-like patterns**
- Grade 1-2, low grade cytology – bland
- Behavior MC ~ EEC*
- DDx:
  - Endocervical mucinous adenoCa
  - MGH
  - Other: Mets, atypical metaplastic proliferations

EEC with mucinous differentiation

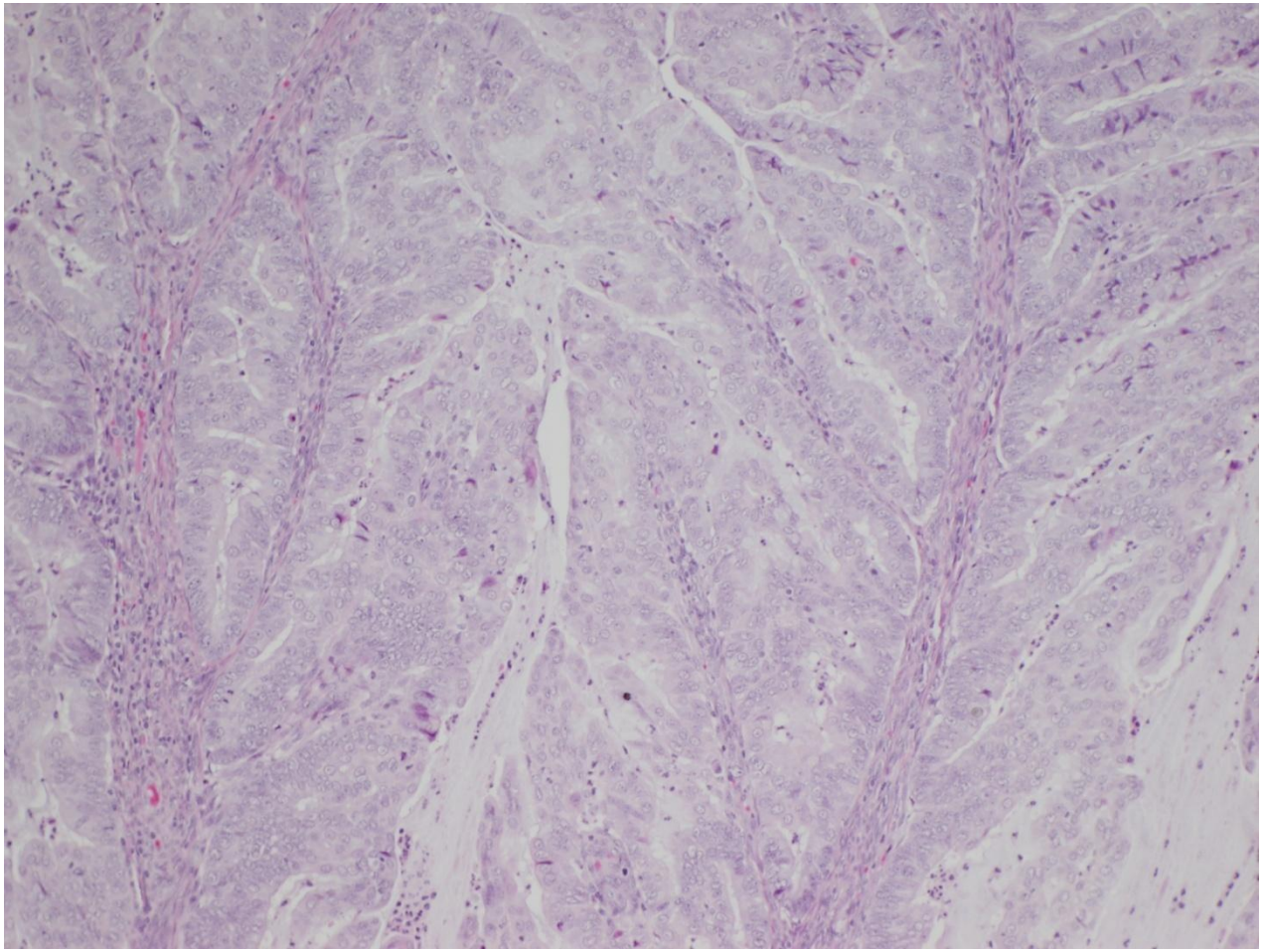

Endocervical-like mucin rich epithelium, complex glands

EEC with mucinous differentiation

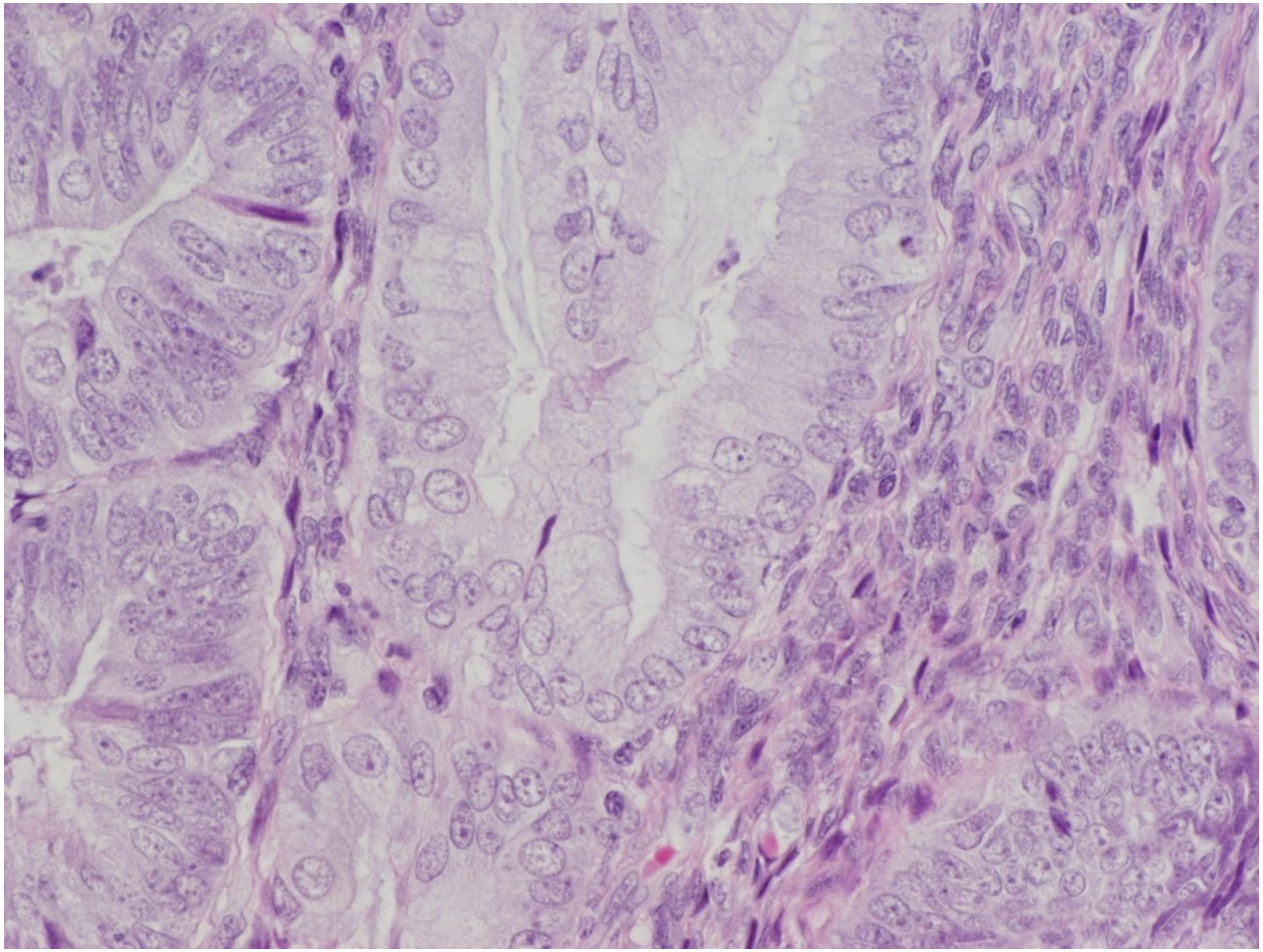

Apical mucin, bland cytology