

CLASSIFICATION AND REPORTING OF COLONIC POLYPS PART I

Objectives

- Review the guidelines for classification and reporting of colonic polyps (recommended by Pathology Working Group under the auspices of the NCCSN of the Canadian Partnership Against Cancer)
- Discuss pitfalls in the diagnosis of malignant colonic polyps

Declaration

- Member of the above mentioned Pathology Working Group

Background

- Colorectal screening programs in all Canadian Provinces
- Detect precursor lesions (primarily adenomas and serrated polyps); identify patients at increased risk for the development of CRC
- Accurate diagnosis of colorectal polyps
- Using a standardized set of diagnostic terms by pathologists from all jurisdictions in Canada

Pathology Working Group

- Pathology Working Group assembled in Sep 2010 under the auspices of the National Colorectal Cancer Screening Network (NCCSN) of the Canadian Partnership Against Cancer (CPAC)
- Primary Objective: Creation of a set of consensus-guidelines for the classification and reporting of colorectal polyps
- Under the leadership of Dr. David Driman

CRC Screening

- Recommended tests for CRC screening in average-risk individuals beginning at age 50 years
- Preferred modality: Colonoscopy every 10 y
- Alternatives
 - FOBT yearly
 - Flexible sigmoidoscopy every 5 y
 - FOBT yearly and flexible sigmoidoscopy every 5 y

CRC Screening

- The timing of follow-up colonoscopy is tailored to the number, size and pathological findings of polyps
- Advanced neoplasia: adenoma ≥ 1 cm, villous adenoma, adenoma with high-grade dysplasia or invasive cancer

Surveillance recommendations for individuals with personal history of colorectal neoplasia

Personal History	Surveillance Recommendation
Prior colonic adenomas ≤2 small tubular adenomas (<1 cm), and only low-grade dysplasia	No earlier than 5 y
Advanced neoplasia or 3-10 adenomas	3 years
> 10 adenomas	Within 3 year
Large sessile polyp with potentially incomplete excision	2-6 Mo
Negative surveillance colonoscopy	No earlier than 5 y
Ulcerative colitis or extensive Crohn's colitis of 8-10 y duration	Surveillance colonoscopy every 1-2 year

Classification of Adenomatous and Serrated Polyps

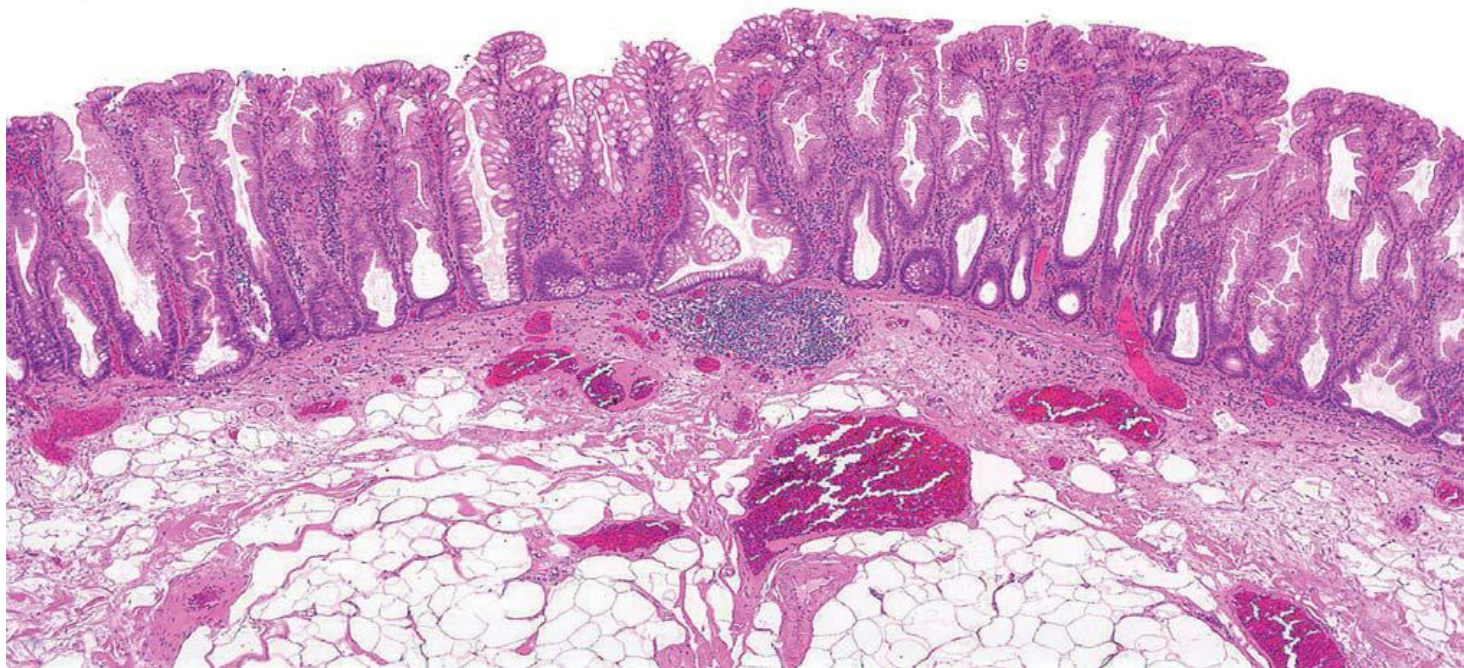
Category	Polyp Type	Qualification of dysplasia
Conventional Adenomas	Tubular adenoma Tubulovillous adenoma Villous Adenoma	\pm high-grade dysplasia /invasive adenocarcinoma
Serrated Adenomas	Sessile Serrated Adenoma/polyp Traditional serrated adenoma Serrated polyp, unclassified	\pm dysplasia (low/high-grade) \pm high-grade dysplasia
Hyperplastic polyp		

- Negative for high-grade dysplasia
- TSA as a conventional adenoma
- Serrated polyp, unclassified: serrated polyps with features indeterminate between one type and another
- SSA/P (with dysplasia)

SSA/P

- Architectural abnormalities
 - Exaggerated deep crypt serration
 - Abnormally located goblet cells
 - Horizontally spreading boot or anchor-shaped crypt bases or dilated crypt bases
 - Upper crypt abnormalities: enlarged vesicular nuclei with prominent nucleoli and upper crypt mitoses.

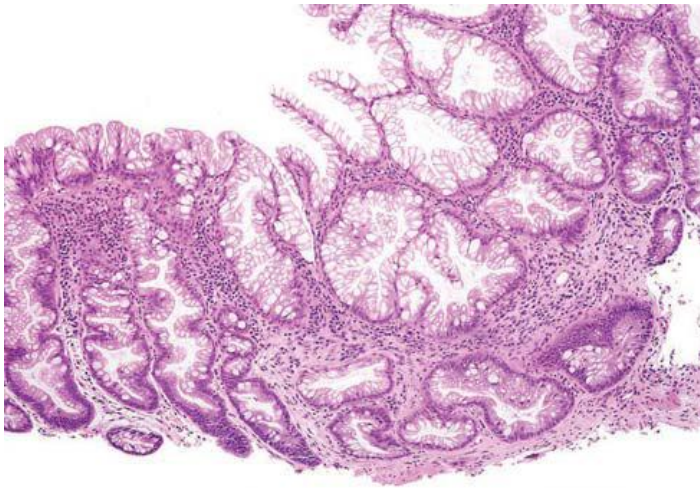
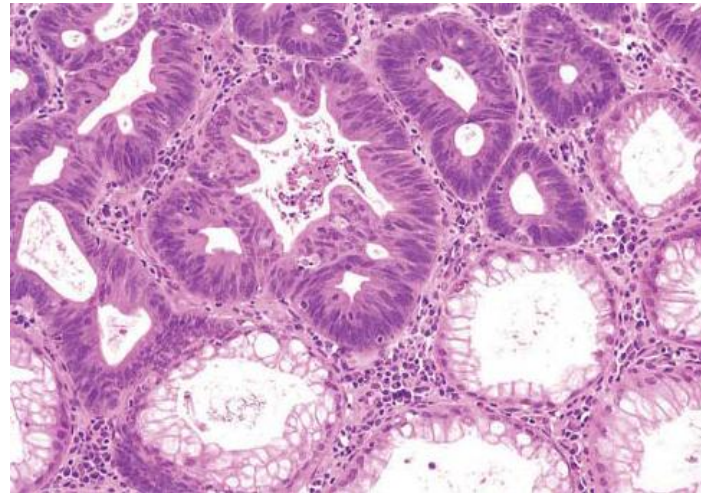
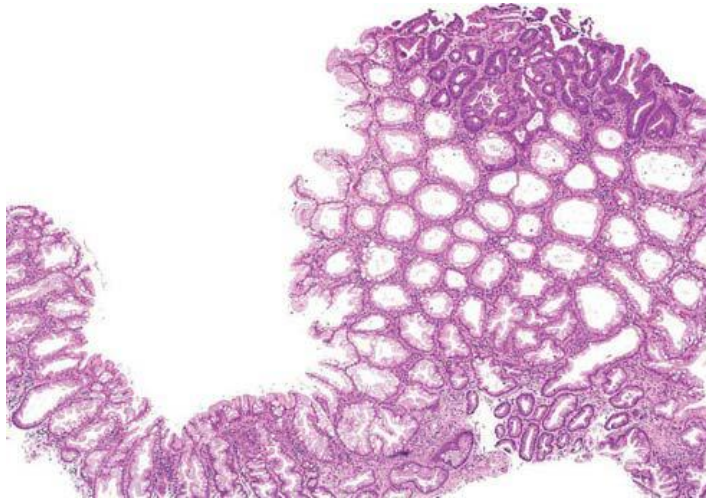
SSA/Ps



SSA/P with Dysplasia

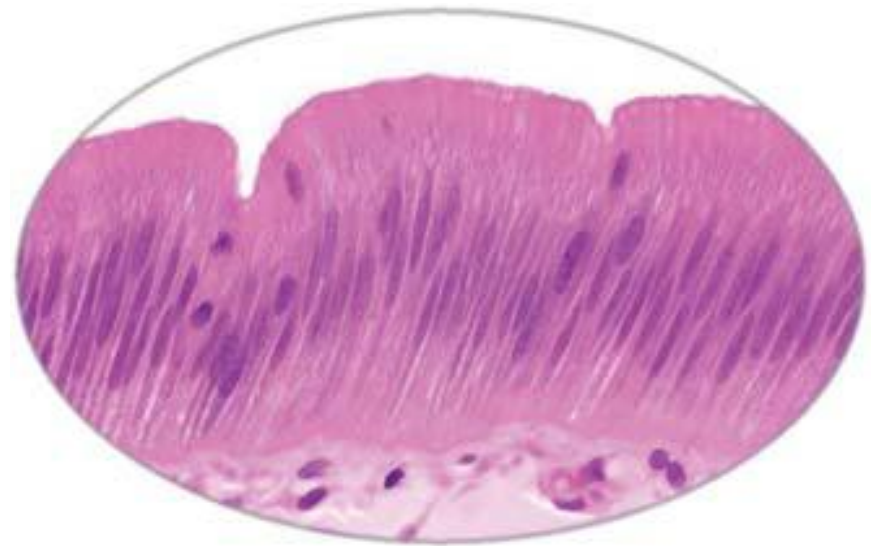
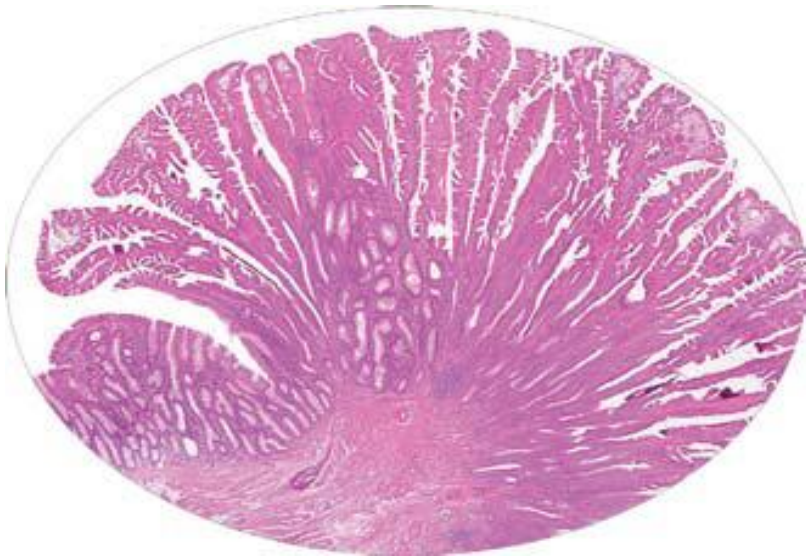“Sessile serrated adenomas with dysplasia are considered to be advanced lesions that have an increased propensity to transform to adenocarcinoma. Complete endoscopic removal is recommended. If complete endoscopic removal cannot be achieved, short-term re-endoscopy and biopsy, or surgical resection should be considered.”

SSA/Ps



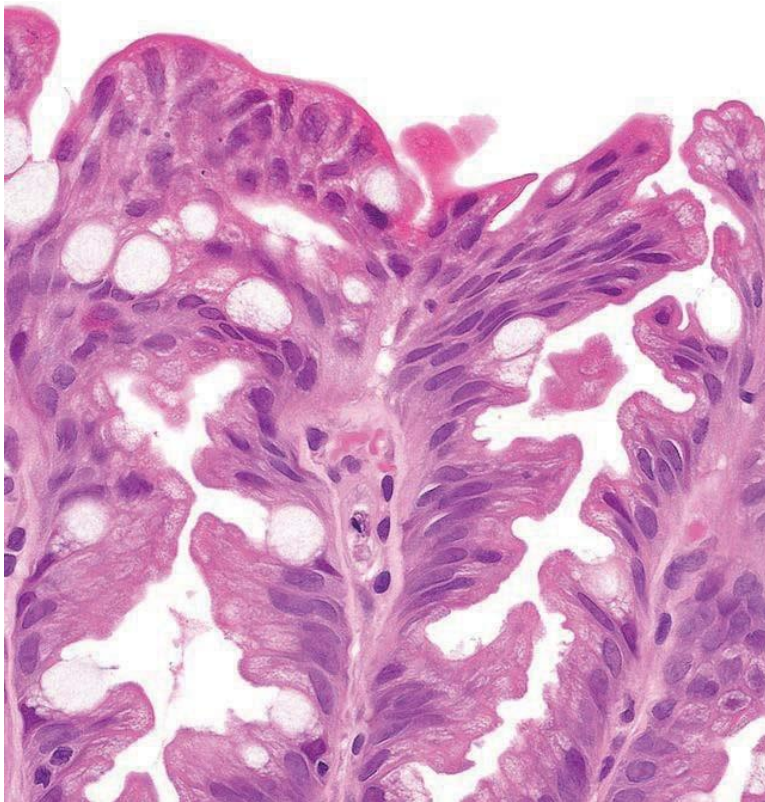
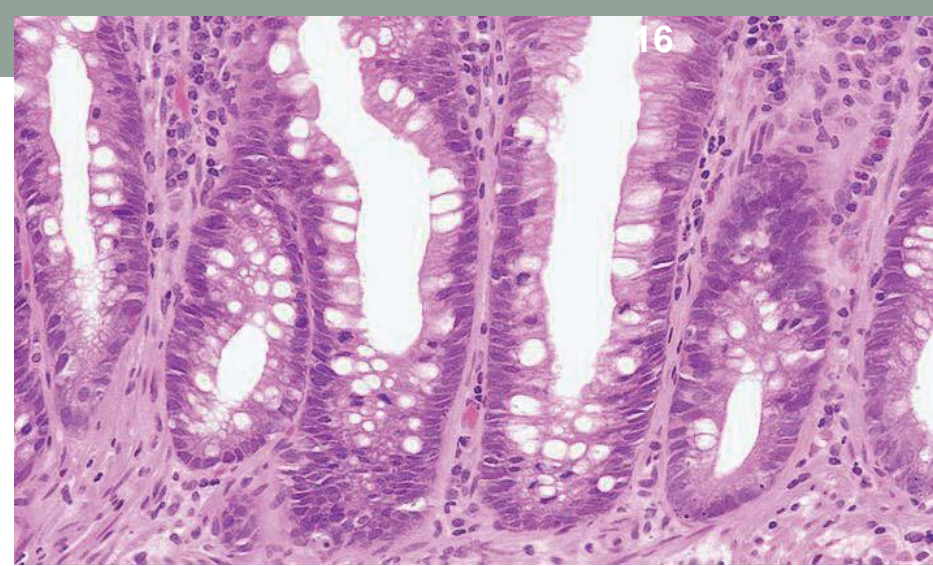
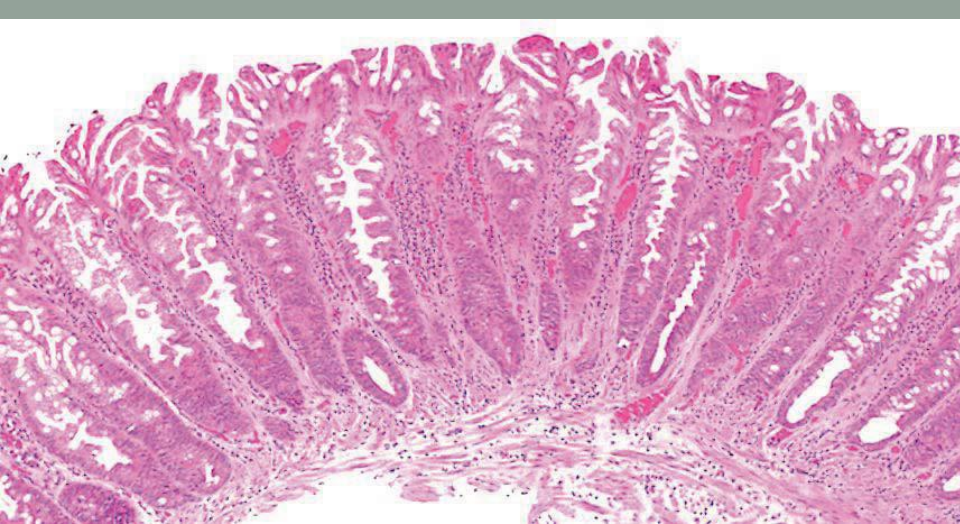
SSA/P with dysplasia
“Mixed SSA/P- adenoma”

TSA

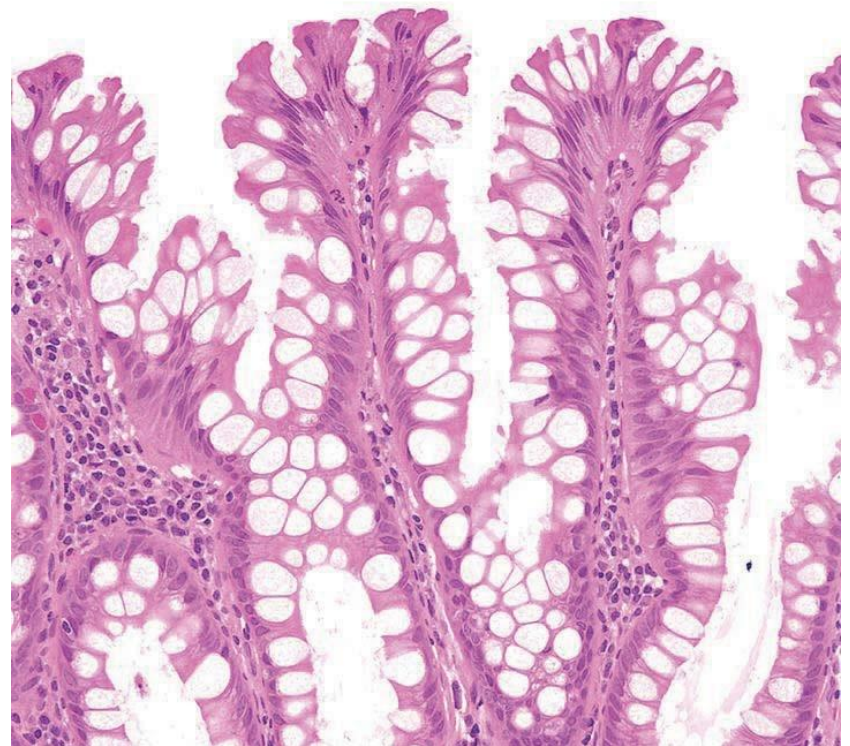

Hyperplastic Polyps

- Subdivided based on their mucin characteristics:
Microvesicular hyperplastic polyps; Goblet cell rich hyperplastic polyps and mucin poor hyperplastic polyp
- Not recommended for above subclassification



Microvesicular HP



Goblet cell HP

Adenomatous Polyps

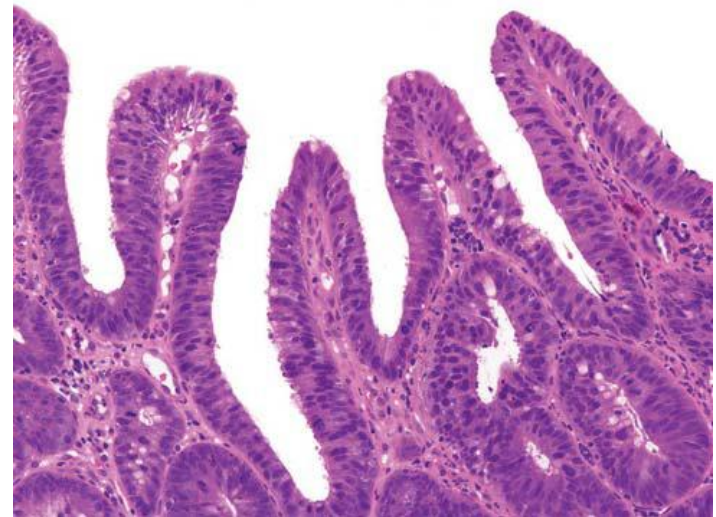
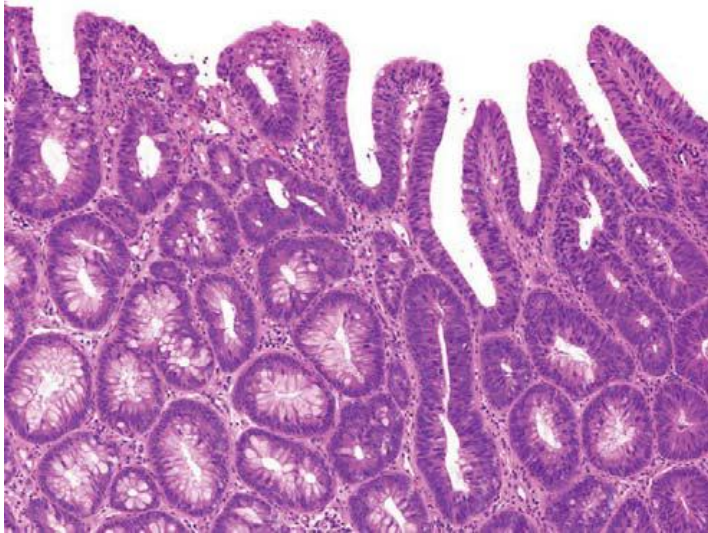
Grading of Dysplasia

- LGD and HGD (carcinoma in-situ or intraepithelial carcinoma is not used)
- Diagnosis of HGD is based on architectural features, supplemented by appropriate cytology
- Abnormal architecture includes cribriform formations with back to back glands, prominent glandular budding and intraluminal papillary tufting. Glandular crowding alone is not a feature of HGD
- Cytological features of HGD: loss of cell polarity, nuclear stratification through the entire thickness of the epithelium, marked enlarged nuclei with prominent nucleoli, atypical mitotic figures, dystrophic goblet cells and prominent apoptosis

Caveats When Diagnosing HGD

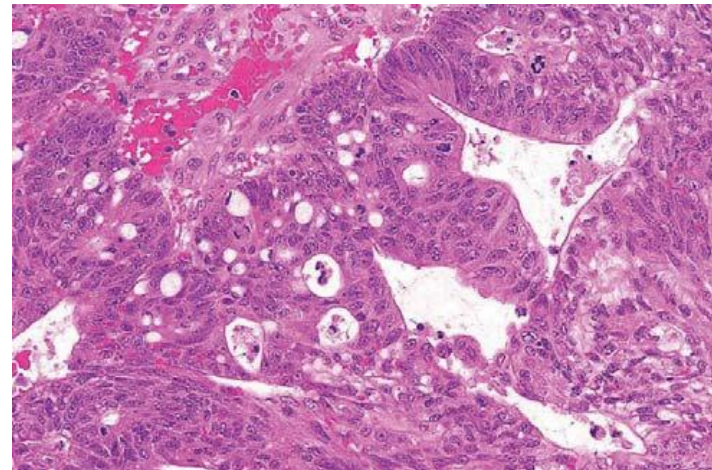
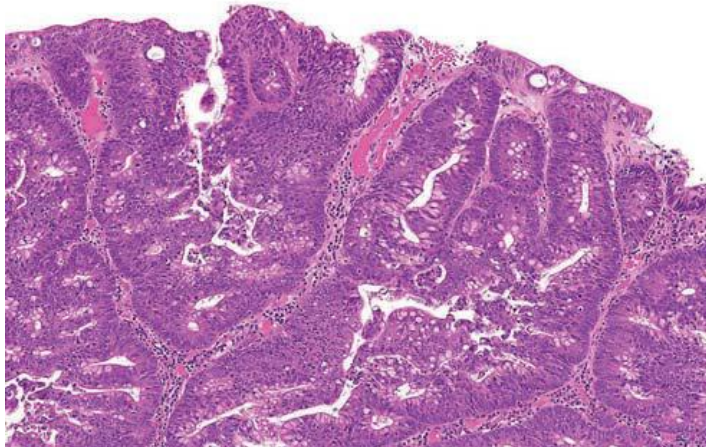
- Over-reliance on cytological abnormalities: cytological abnormalities should not be used alone for the diagnosis of HGD (except marked abnormalities or in small biopsy)
- Over-calling architectural complexity: there is often a minor degree of budding in tubular adenoma which does not constitute HGD
- Over-calling surface changes: stem from trauma, erosion or prolapse
- Insufficient extent of abnormalities: typical abnormalities should usually involve more than two crypts

LGD

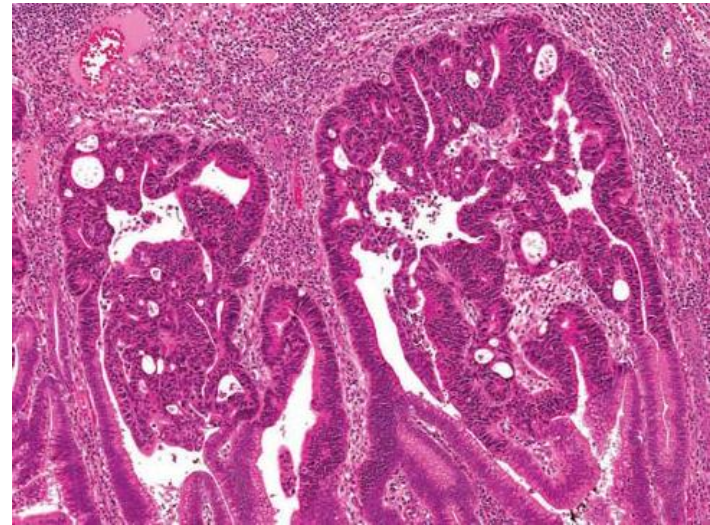
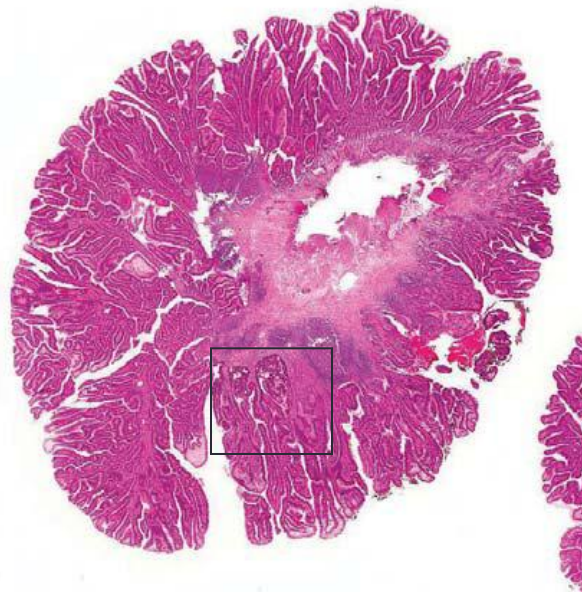


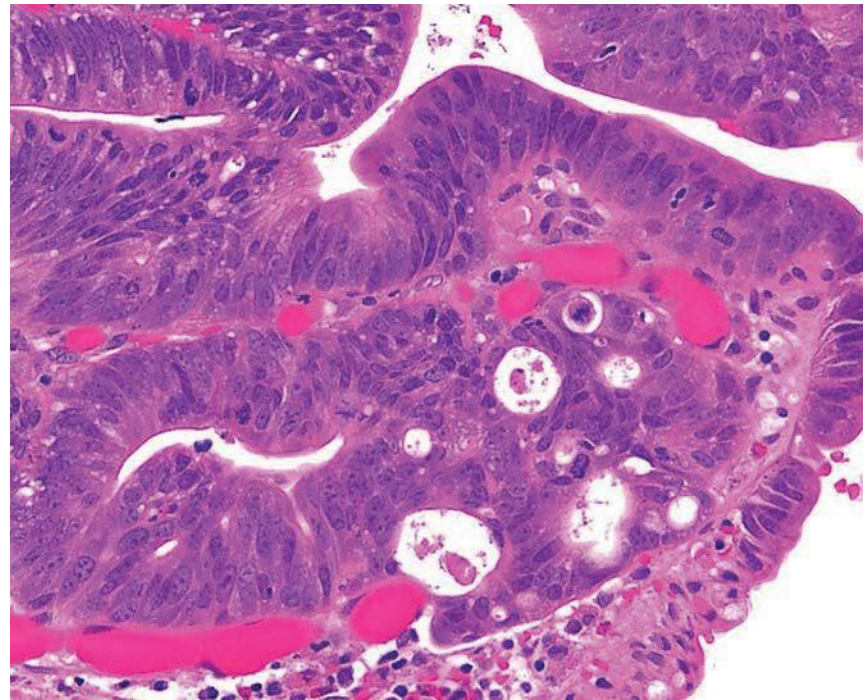
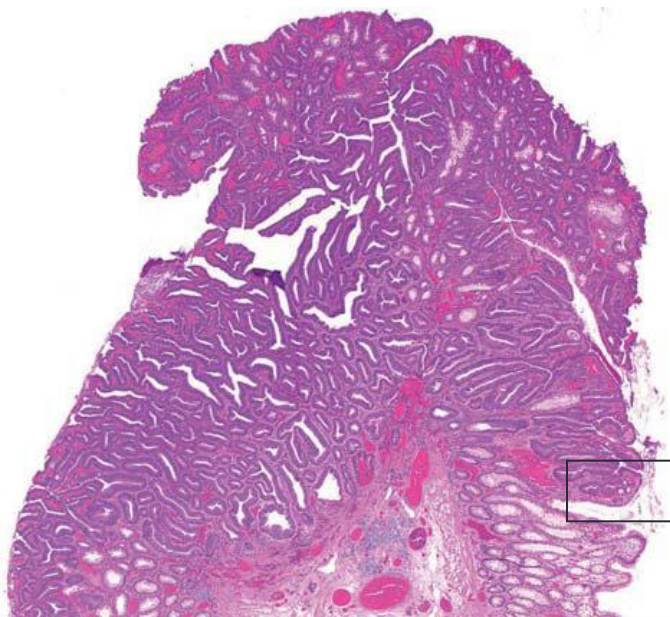
Nuclear stratification through full thickness of epithelium is not a criterion for HGD

HGD



HGD

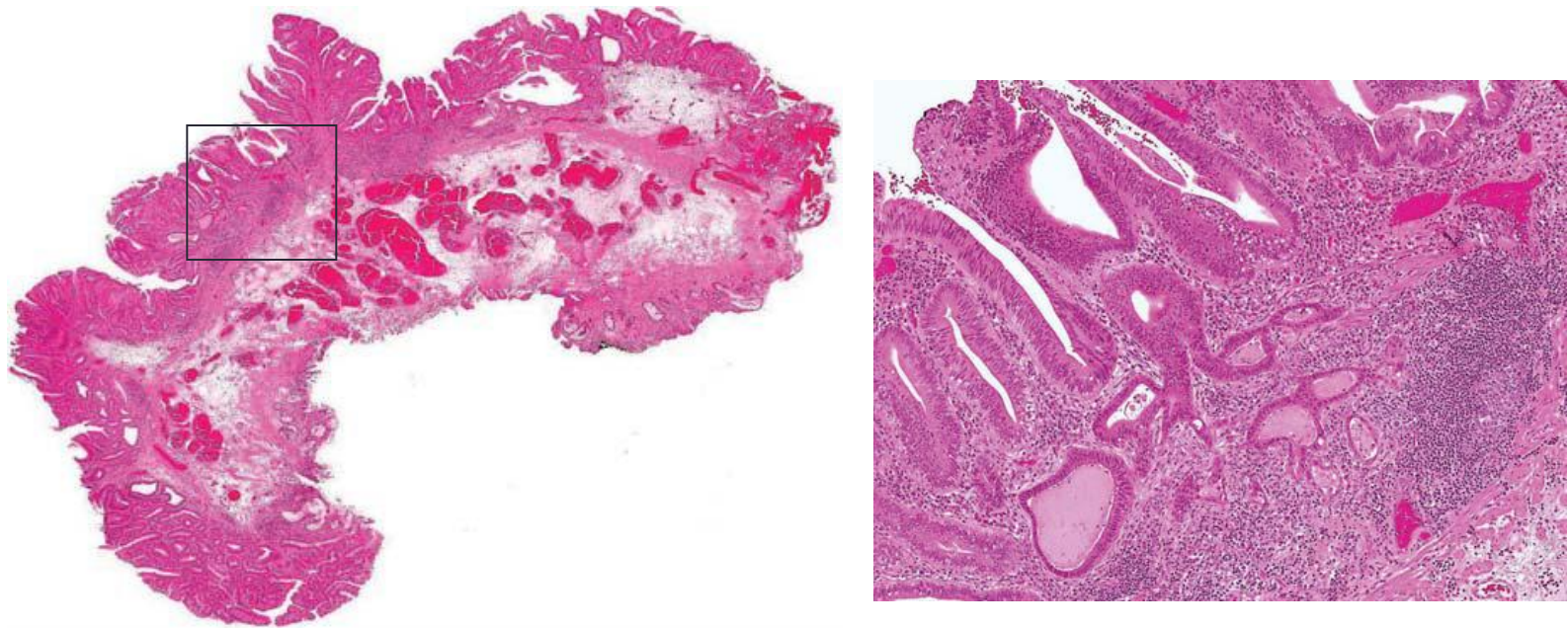




Focal cribriforming only; this is LGD

HGD vs. Intramucosal Carcinoma

- WHO: HGD instead of intramucosal carcinoma (i.e., invasion of lamina propria \pm muscularis mucosae)
- Rationale: negligible risk of malignant biological behavior; do not require further surgery
- Recommendation: use the term HGD with a comment to explain the term of “HGD” in this case



HGD rather than Intramucosal carcinoma

Adenomatous Polyps

Assessment of Villosity

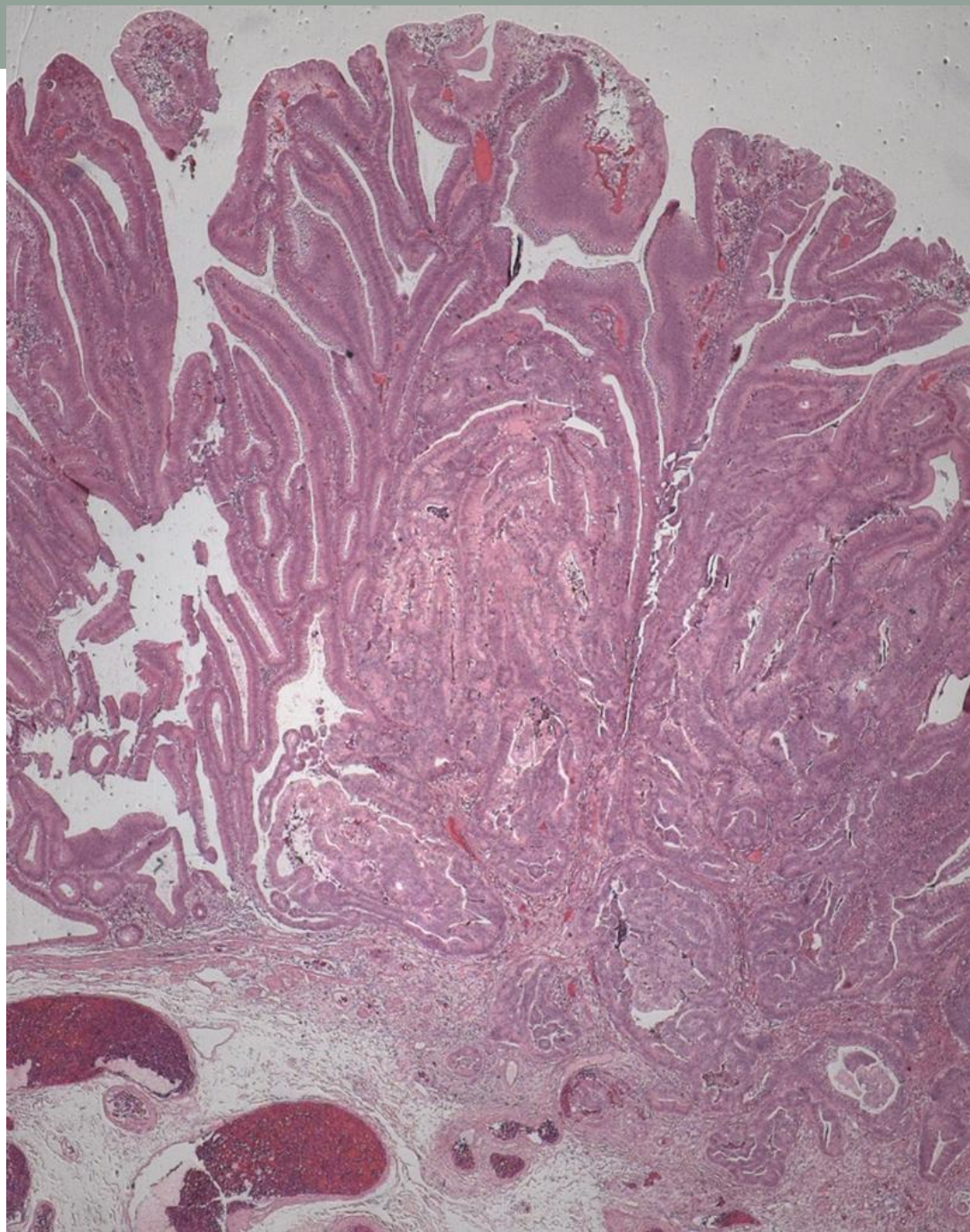
- Polyps in which less than 20-25% of the polyp is villous are classified as tubular
- Polyps in which greater than 75-80% is villous are classified as villous
- All other polyps are tubulovillous adenoma
- Criteria can only be used reliably in polypectomy and resection specimen or tissue fragments large enough to assess the various proportions present
- “At least tubulovillous”: small biopsy of a large polyp when at least one villous is present
- It may be difficult to distinguish “true” villi from exaggerated, axially sections crypts. In general, it is better to err on the side of under-diagnosis of villous changes, especially in small (<1 cm) adenomas.

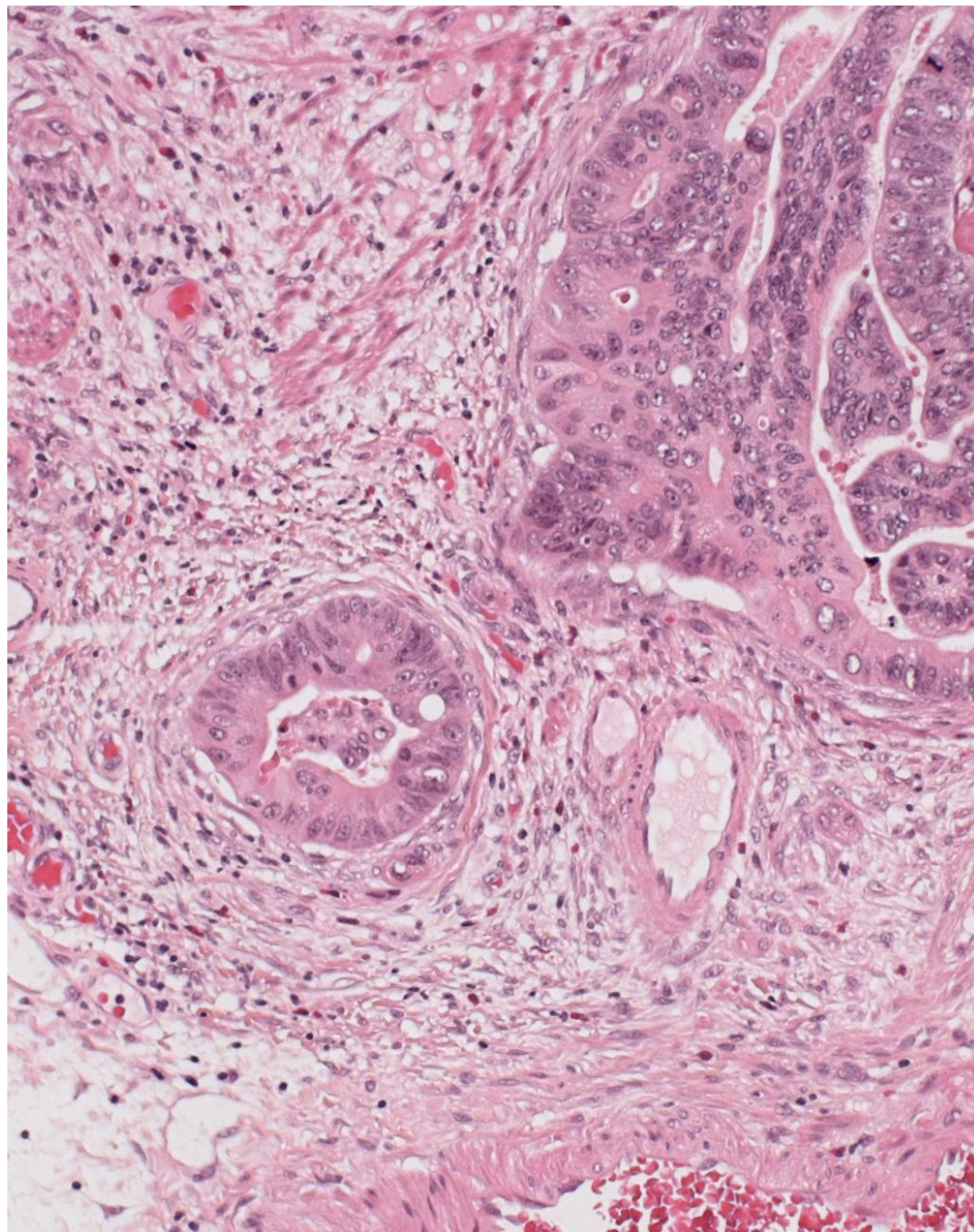
Malignant Polyps

- Adenomatous polyps with invasive adenocarcinoma (defined as invasion through the muscularis mucosae into the submucosa)
- Pathological features must be reported in malignant polyps
 - Presence or absence of any amount of poorly differentiated adenocarcinoma
 - Presence or absence of angiolymphatic invasion
 - Distance of invasive carcinoma from the margin of resection (a distance of 1mm or less is considered to represent a positive margin)

Pseudoinvasion

- Pedunculated polyps in sigmoid colon
- Submucosal glands surrounded by lamina propria
- Do not have cytoarchitectural features of malignancy
- Hemorrhage and hemosiderin in the surrounding submucosa and no desmoplastic stromal reaction
- Acellular mucin pools
- Absence of HGD





Reporting Completeness of Excision

- Malignant polyp
- All polyps with HGD
 - May not be assessable due to fragmentation (stated in the report)
- Adenoma without HGD: not recommend
 - avoid to use “ may not be completely excised”, or “completeness of excision can not be assessed.

QA

- Identify cases that were called “positive for invasive adenocarcinoma” in colonic biopsies but negative for malignancy in subsequent resected specimens (excluded rectal biopsies)
- Reviewed reports of cases from 2000 -2010 (total 768)
- 32 cases (4%) with no evidence of malignancy in resected specimens
- We reviewed the slides of original biopsies:
 - 4 cases (0.5% of total reviewed cases) were reclassified as over-diagnosis (false positive)
 - 17 cases remained classified as malignant polyps
 - 11 cases were considered as difficult polyps for classification

Report for Malignant Polyps

- For 17 cases of malignant polyps:
 - 9 had complete reports
 - 8 had incomplete reports, including:
 - 5 missing comment about LVI
 - 2 missing comment about differentiation
 - 3 missing comment about margin