Pleuropulmonary Pathology of Autoimmune Connective Tissue Diseases

Mathieu C. Castonguay, MD, FRCP(C)

AP Divisional Web Conference

November 19, 2013

Capital Health

DALHOUSIE UNIVERSITY
Inspiring Minds

I have no relevant actual or potential conflict of interest in relation to this presentation

Learning Objectives

At the end of this session, participants will be able to:

- understand the differences between the histologic patterns of pleuropulmonary diseases associated with connective tissue diseases (CTDs)
- distinguish the most frequent forms of interstitial lesions seen in patients with CTDs

Clinical Background

- CTDs
  - group of autoimmune disorders that affect mainly (but not exclusively) joints and muscles
    - rheumatoid arthritis (RA)
    - systemic lupus erythematosus (SLE)
    - Sjögren syndrome
    - systemic sclerosis (SSc)
    - inflammatory myopathies
    - systemic vasculitides
    - ankylosing spondylitis

Clinical Background

- CTDs
  - diagnosis can be difficult
  - ~50% remain “undifferentiated” one year after presentation

Clinical Background

- Pulmonary involvement in CTDs
  - incidence variable, but increasing
  - may be secondary
    - infection
    - drug toxicity
    - amyloidosis
    - aspiration
    - musculoskeletal dysfunction
    - neoplasia
    - paraneoplastic

Clinical Background

- Pulmonary involvement in CTDs
  - may be initial CTD presentation

Clinical Background

- Pulmonary involvement in CTDs

CTD	Pulmonary involvement (%)
RA	40
SLE	50-70
Sjögren	9-75
SSc	40-60
PM/DM	60

Clinical Background

- Pulmonary involvement in CTDs
  - may affect any of the anatomical compartments
    - airways
    - alveolated parenchyma
    - vasculature
    - pleura
  - reflects clinical presentation

Anatomic Pulmonary Compartments

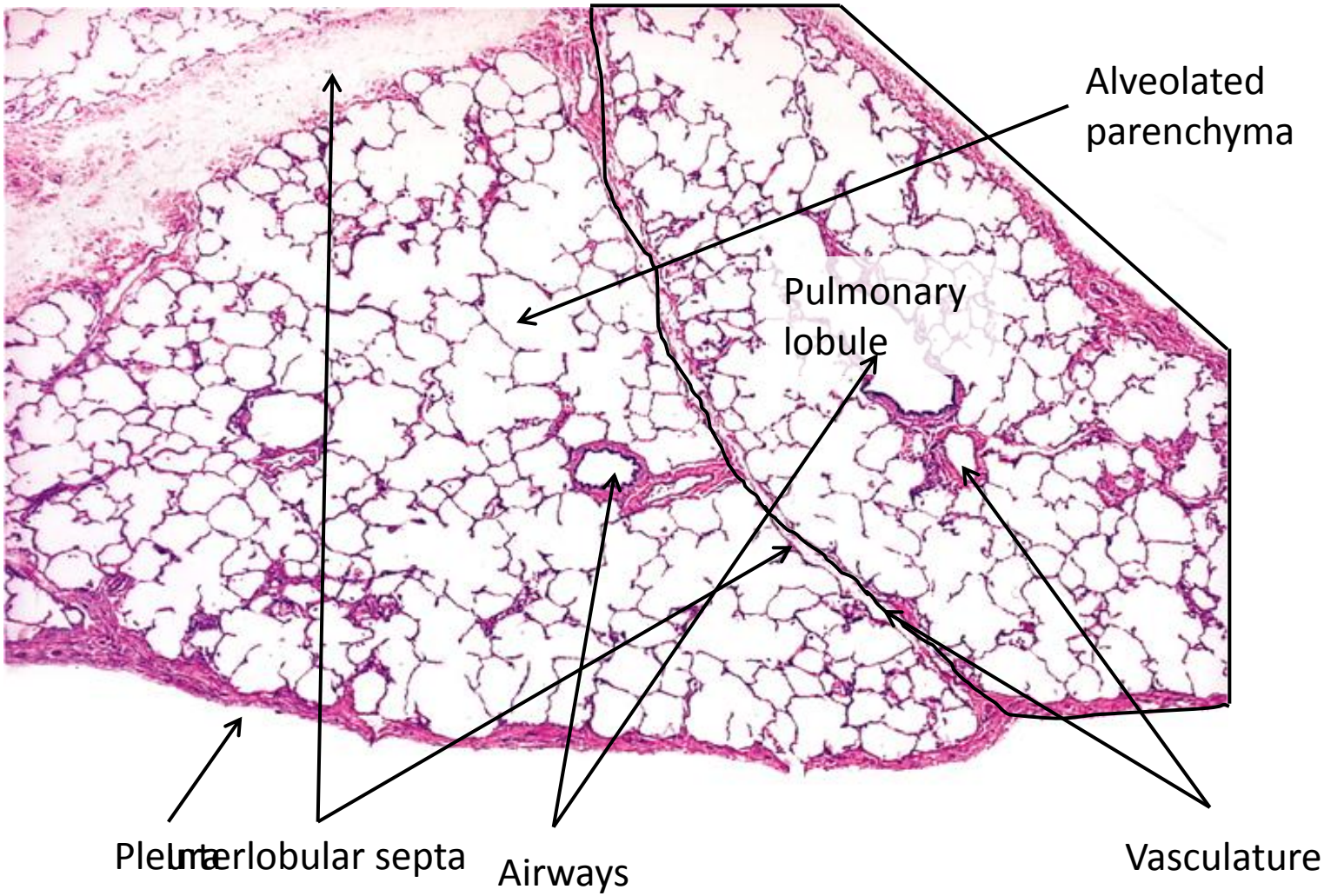

Mills SE, *Histology for Pathologists*, 3rd Ed, Figure 18-13B

Parenchymal lesions

- Overlap with idiopathic lung diseases

TABLE 2. CATEGORIZATION OF MAJOR IDIOPATHIC INTERSTITIAL PNEUMONIAS

Category	Clinical–Radiologic–Pathologic Diagnoses	Associated Radiologic and/or Pathologic–Morphologic Patterns
Chronic fibrosing IP	Idiopathic pulmonary fibrosis	Usual interstitial pneumonia
	Idiopathic nonspecific interstitial pneumonia	Nonspecific interstitial pneumonia
Smoking-related IP*	Respiratory bronchiolitis-interstitial lung disease	Respiratory bronchiolitis
	Desquamative interstitial pneumonia	Desquamative interstitial pneumonia
Acute/subacute IP	Cryptogenic organizing pneumonia	Organizing pneumonia
	Acute interstitial pneumonia	Diffuse alveolar damage

Travis WD, *et al*. *Am J Respir Crit Care Med*, 2013; 188 (6): 733-48

Parenchymal lesions

- Usual interstitial pneumonia (UIP)
  - can be seen with any of the CTDs
  - most common ILD pattern in RA
    - often men, smokers
    - 1 - 4% of RA patients

Parenchymal lesions

- Usual interstitial pneumonia (UIP)
  - poor prognosis, but better than in patients with idiopathic UIP

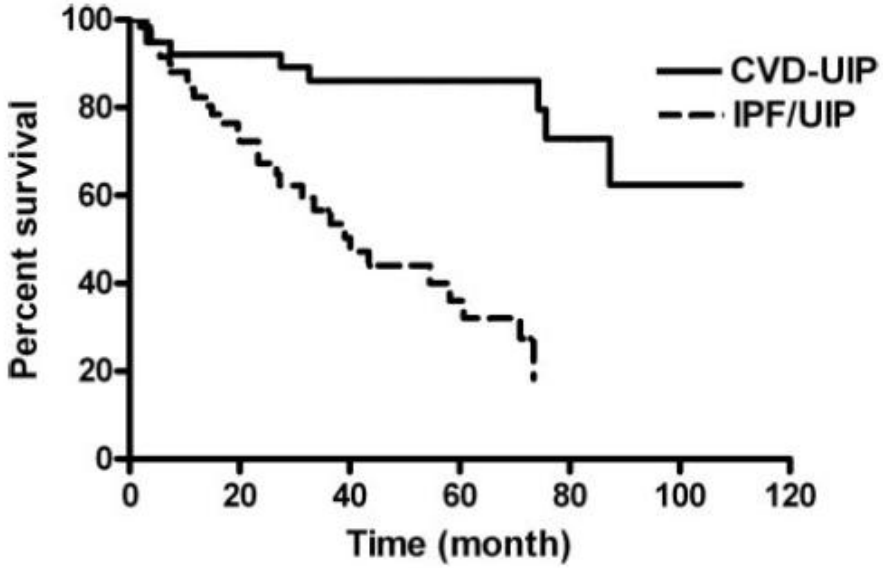

FIGURE 1. Comparison of the survival curves for CVD-UIP and IPF/UIP patients.

Song JW, *et al*. *Chest*, 2009; 136 (1): 23-30

Parenchymal lesions

- Usual interstitial pneumonia (UIP)
  - serology recommended to evaluate for the possibility of associated CTD
    - RF, anti-cyclic citrullinated peptide, ANA

Raghu G, *et al*. *Am J Respir Crit Care Med*, 2011; 183 (6): 788-824

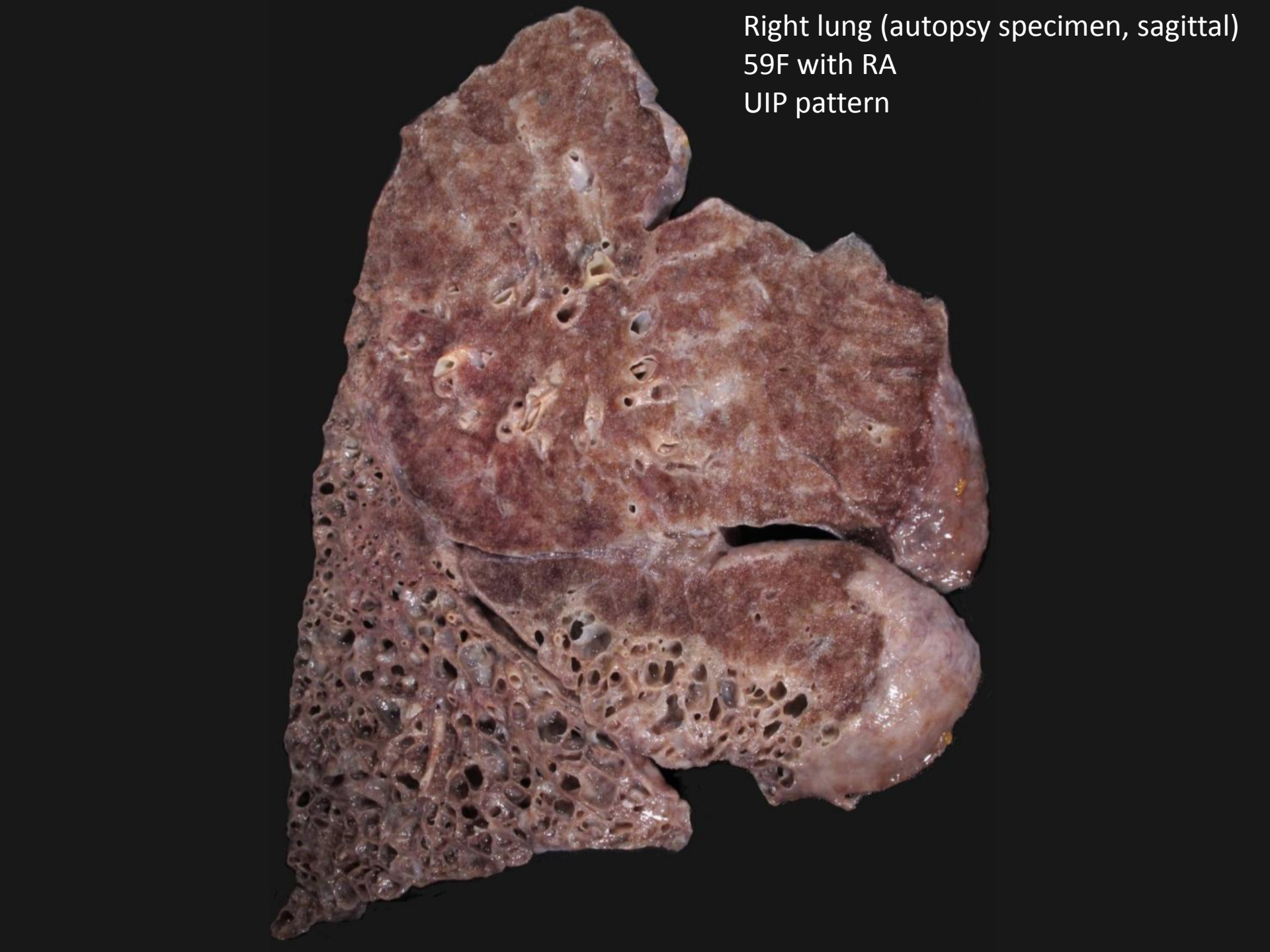
Right lung (autopsy specimen, sagittal)
59F with RA
UIP pattern

Parenchymal lesions

- Histopathology of UIP
  - key features
    - architectural distortion
    - temporal heterogeneity
    - spatial heterogeneity

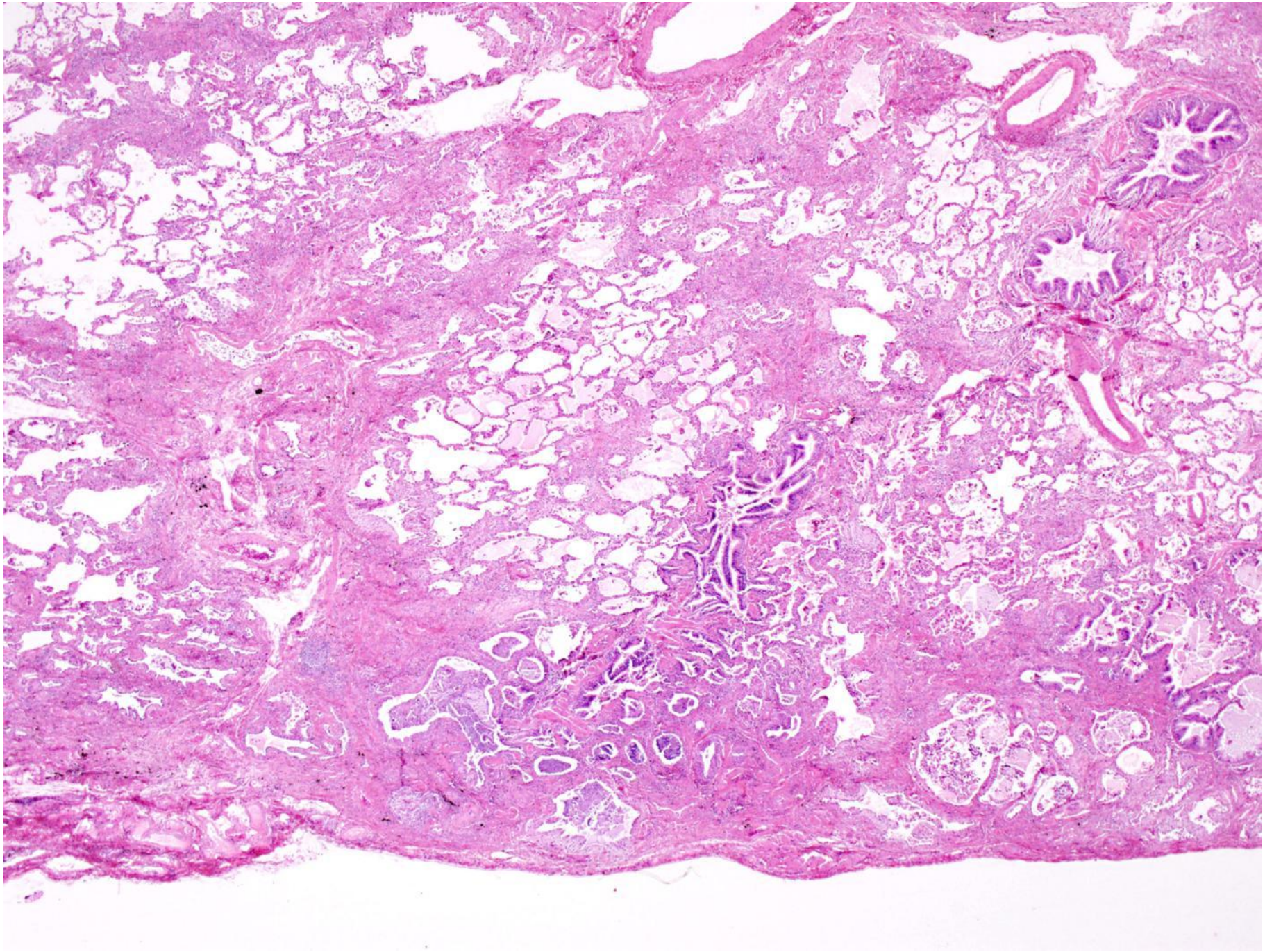

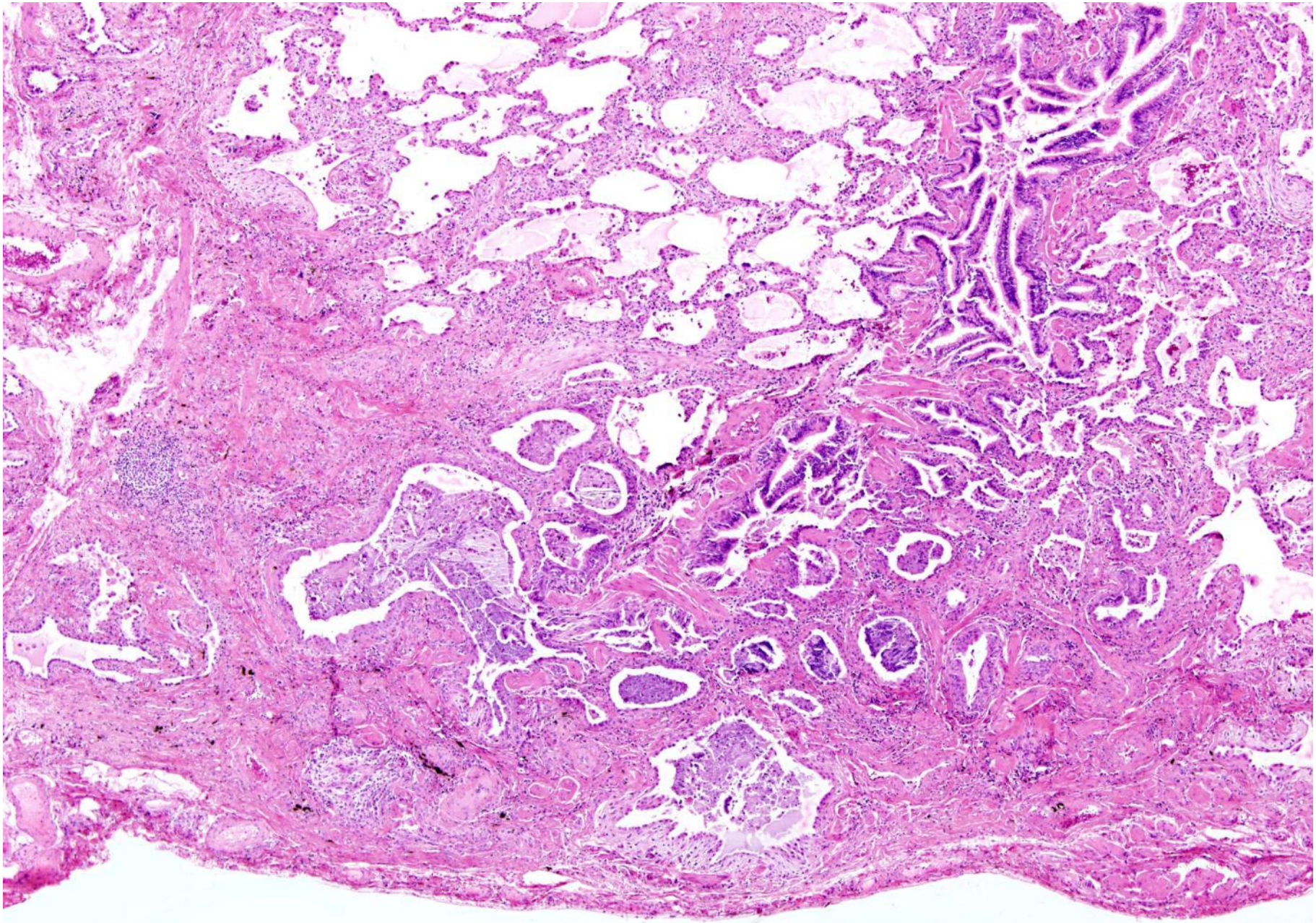

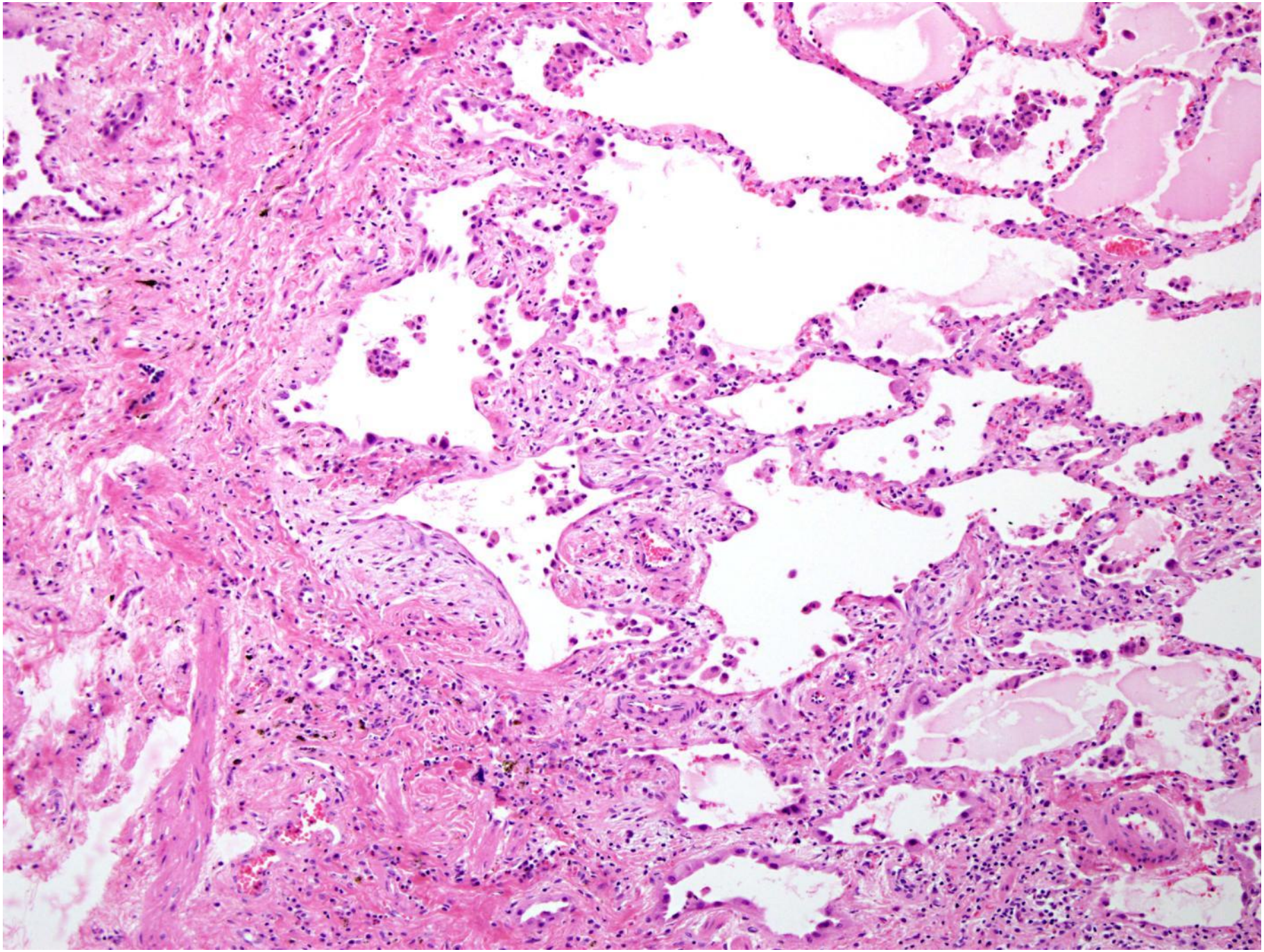

Parenchymal lesions

- Histopathology of UIP
  - Clues to CTD association
    - germinal centres
    - fewer fibroblast foci
    - smaller honeycomb spaces
    - more inflammation

Song JW, *et al*. *Chest*, 2009; 136 (1): 23-30

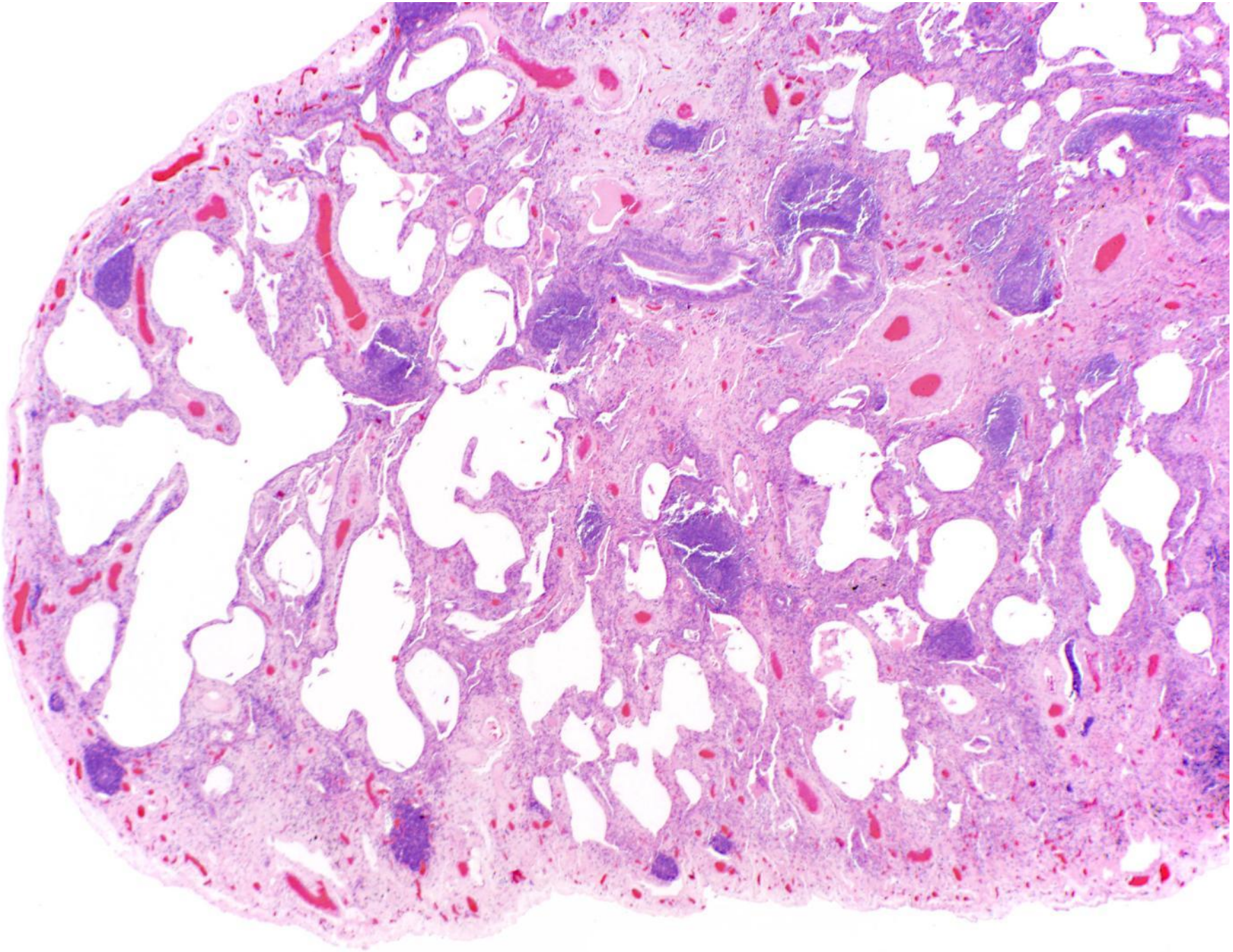

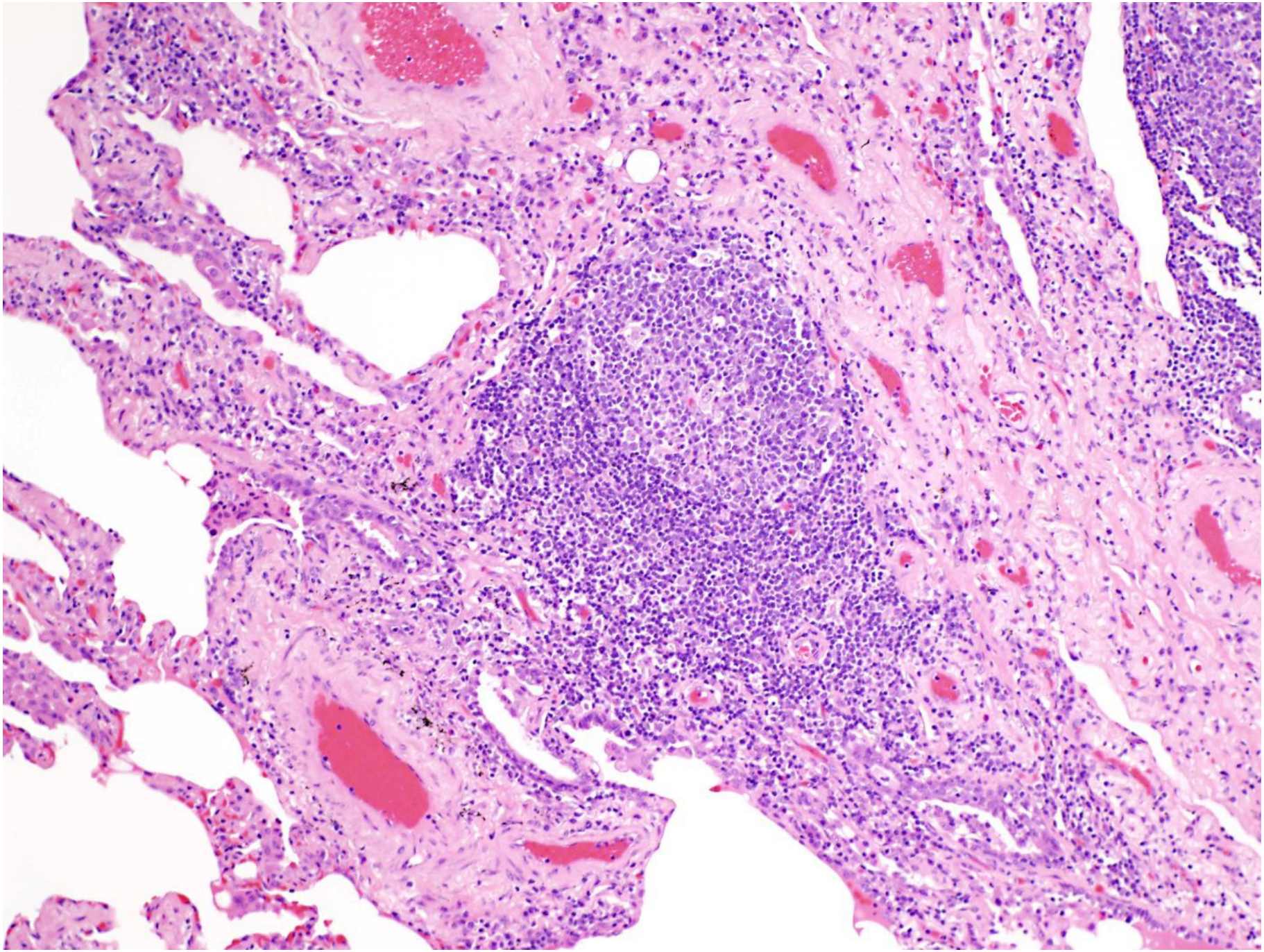

Parenchymal lesions

- Non-specific interstitial pneumonia (NSIP)
  - can be seen with any of the CTDs
  - most common ILD pattern in majority of CTDs
  - better prognosis than UIP

Parenchymal lesions

- Non-specific interstitial pneumonia (NSIP)
  - some routinely perform serology in NSIP patients to evaluate for CTD association

Kinder BW. *Clin Chest Med*, 2012; 33 (1): 111-21

Parenchymal lesions

- Histopathology of NSIP
  - two subtypes: cellular and fibrosing
  - key features
    - temporal uniformity
    - spatial uniformity
    - relatively preserved architecture

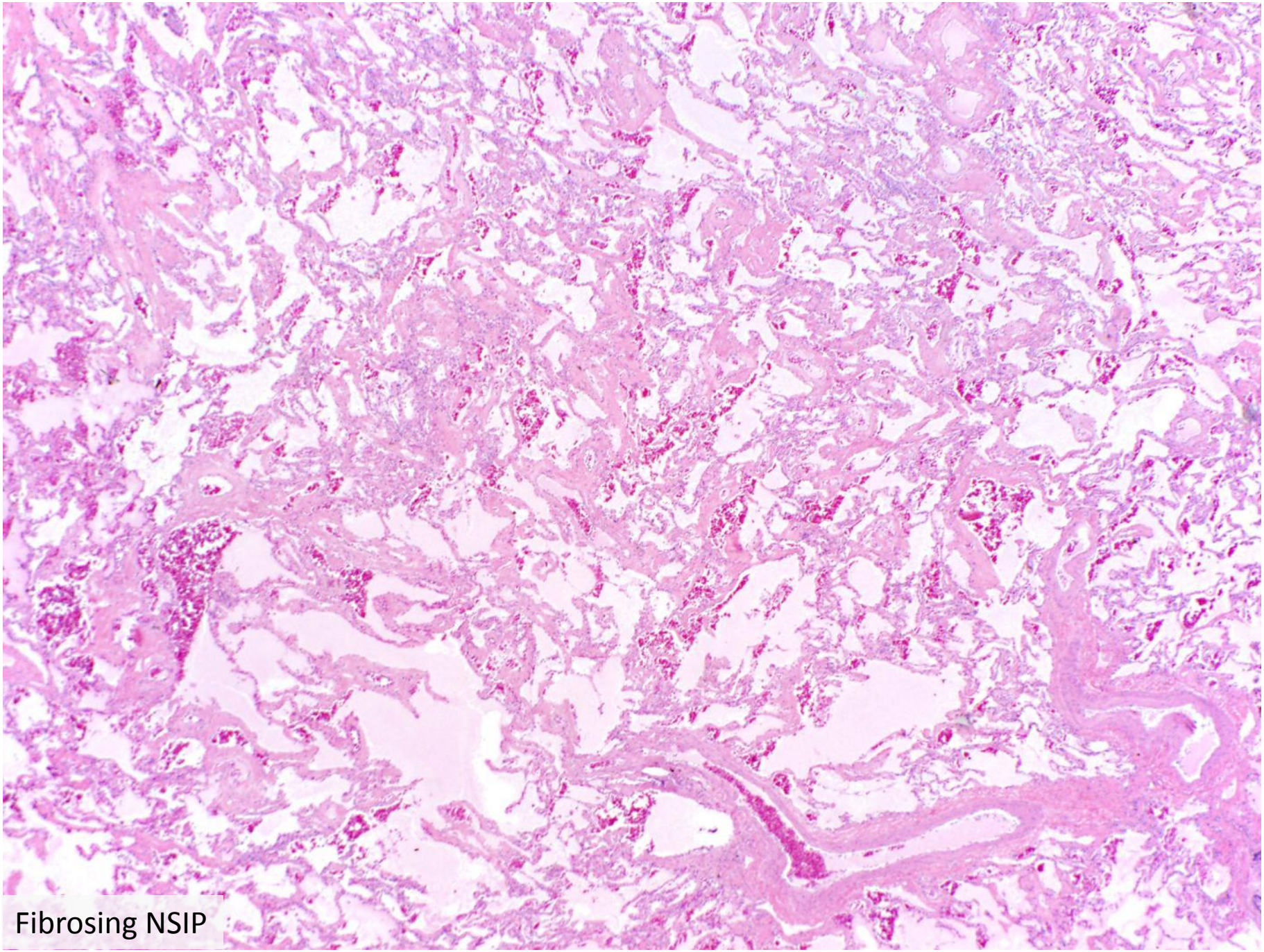
Fibrosing NSIP

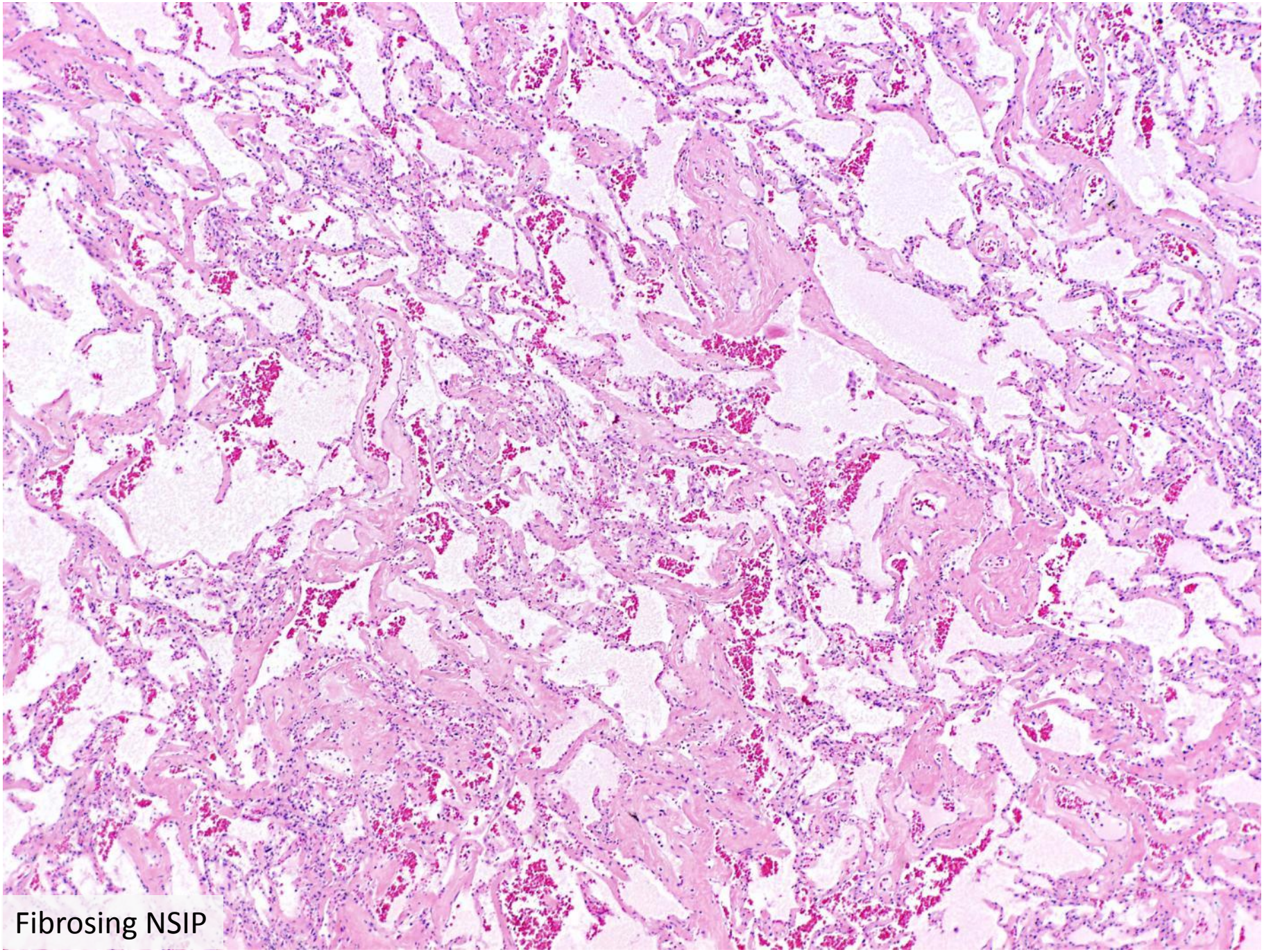
Fibrosing NSIP

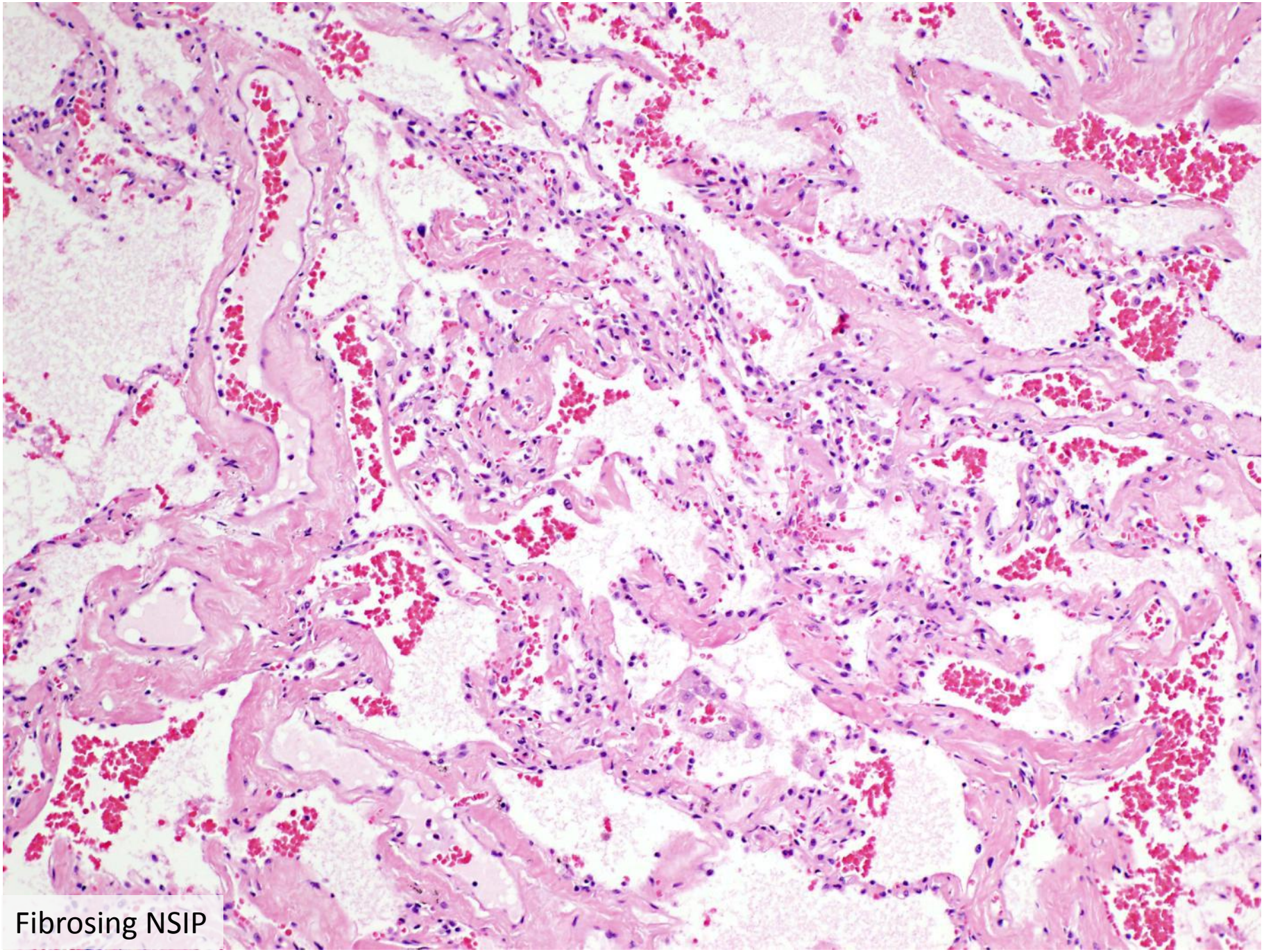
Fibrosing NSIP

Parenchymal lesions

- Organizing pneumonia (OP)
  - can be seen with any of the CTDs, albeit less commonly than fibrosing ILD
  - good prognosis
    - responds to corticosteroids

Parenchymal lesions

- Histopathology of OP
  - key features
    - intraluminal organizing fibrosis in airspaces
    - patchy distribution
    - preserved architecture
    - mild chronic interstitial inflammation

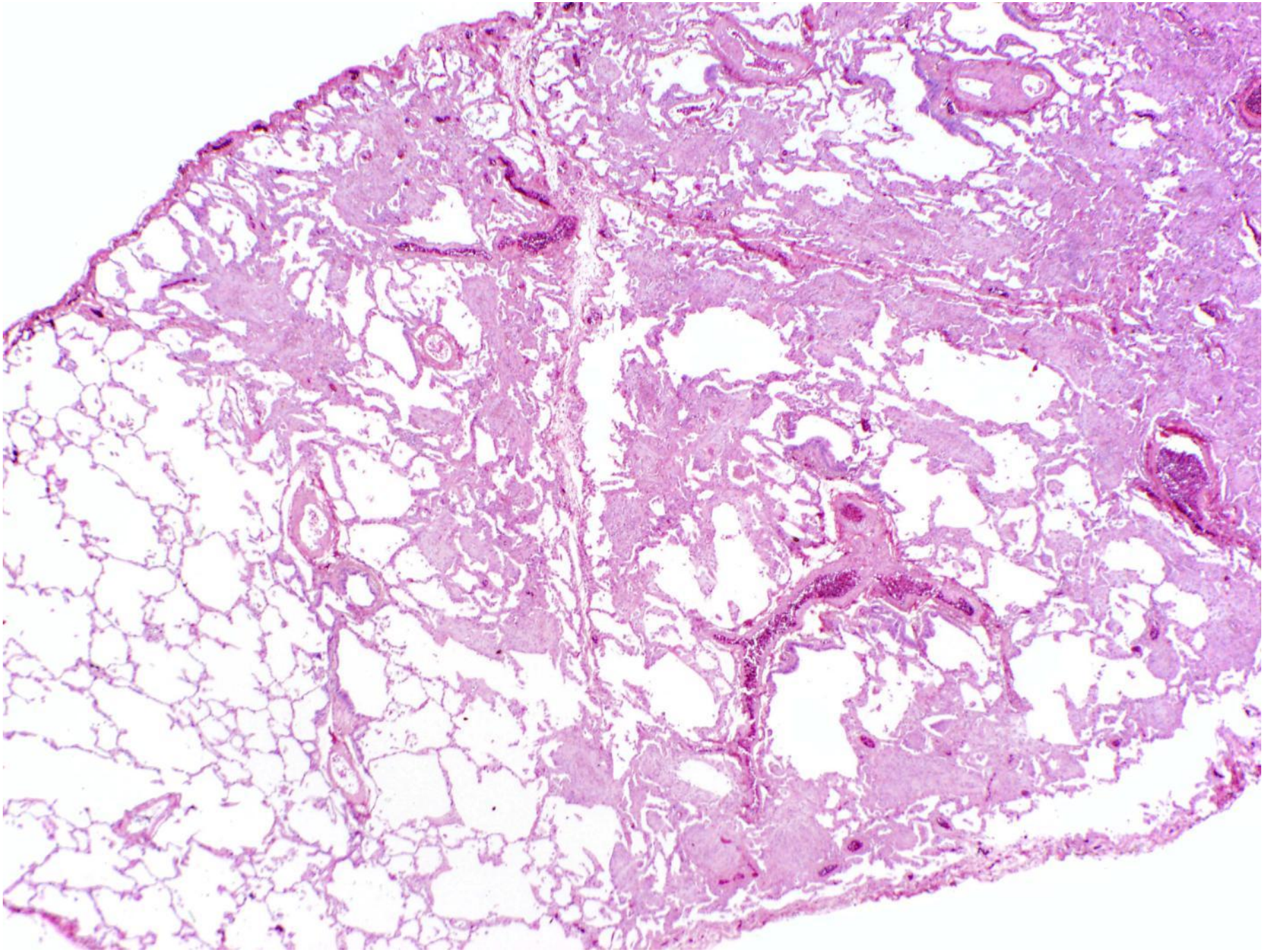

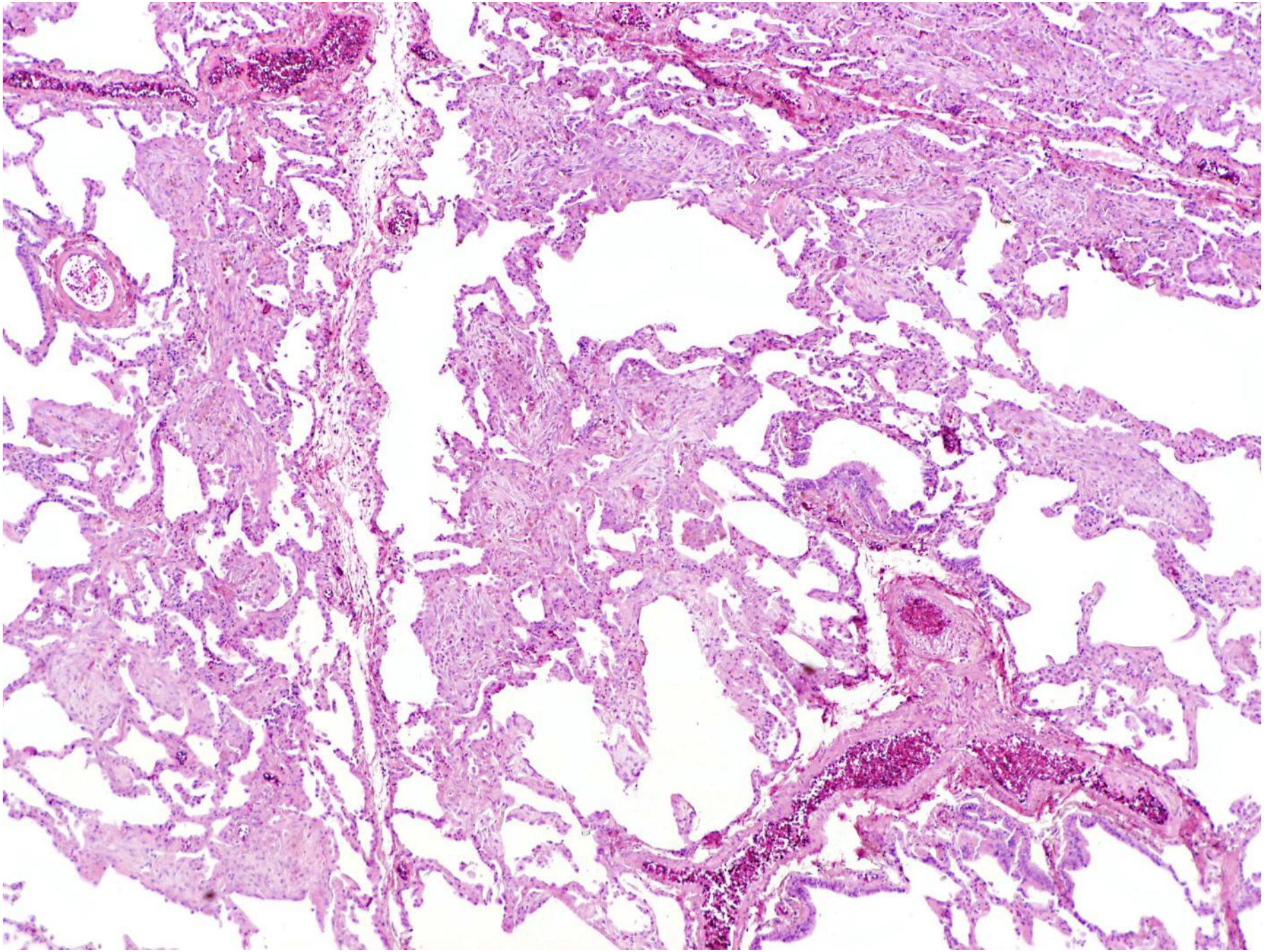

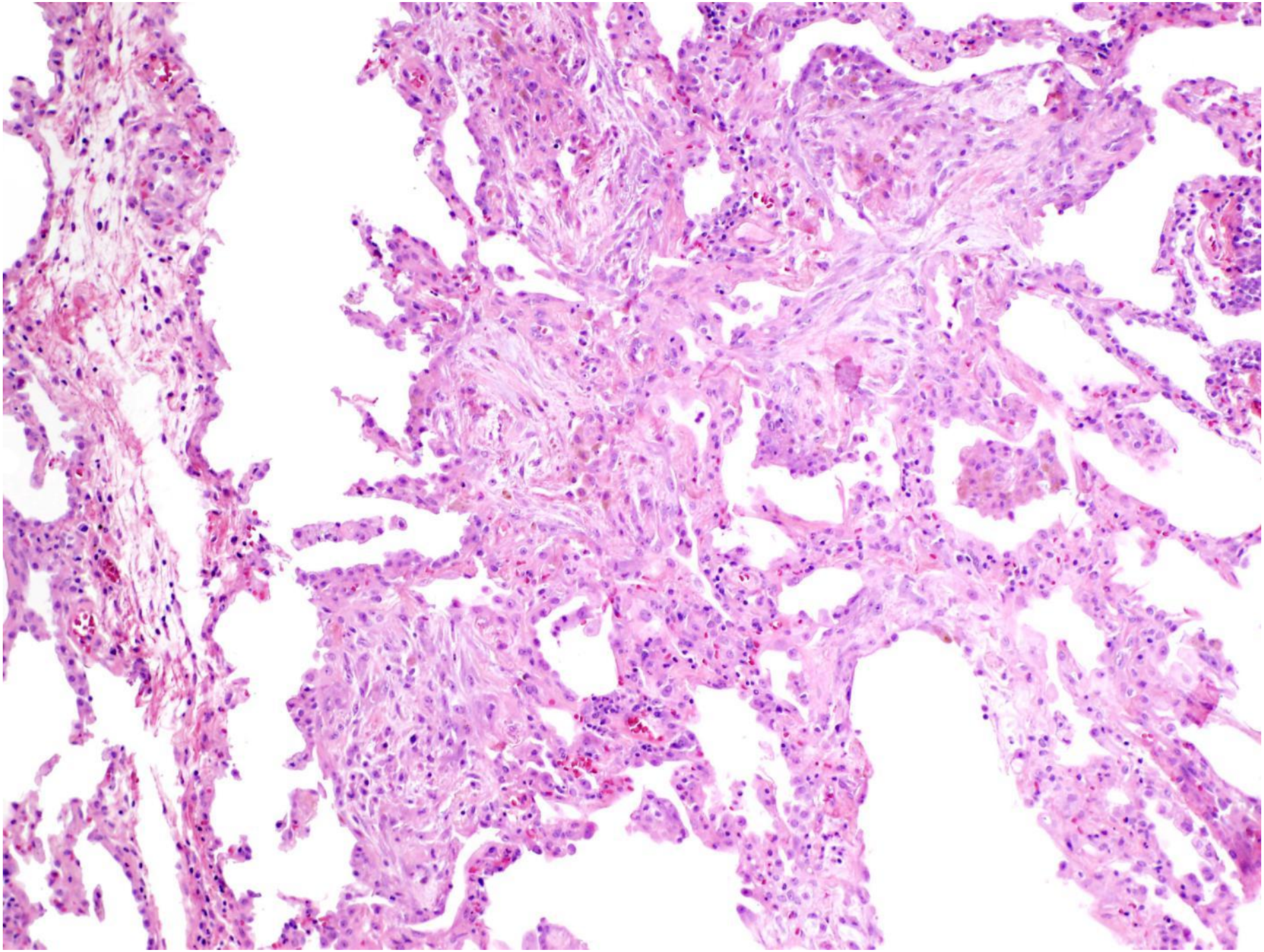

Parenchymal lesions

- Diffuse alveolar damage (DAD)
  - can be seen with any of the CTDs, albeit less commonly than fibrosing ILD
  - poor prognosis
  - may occur alone, or as an acute exacerbation of pre-existing fibrosing ILD

Parenchymal lesions

- Histopathology of DAD
  - acute, organizing, and fibrosing phases
  - key features
    - diffuse distribution
    - temporal uniformity
    - alveolar septal thickening by organizing fibrosis
    - hyaline membranes

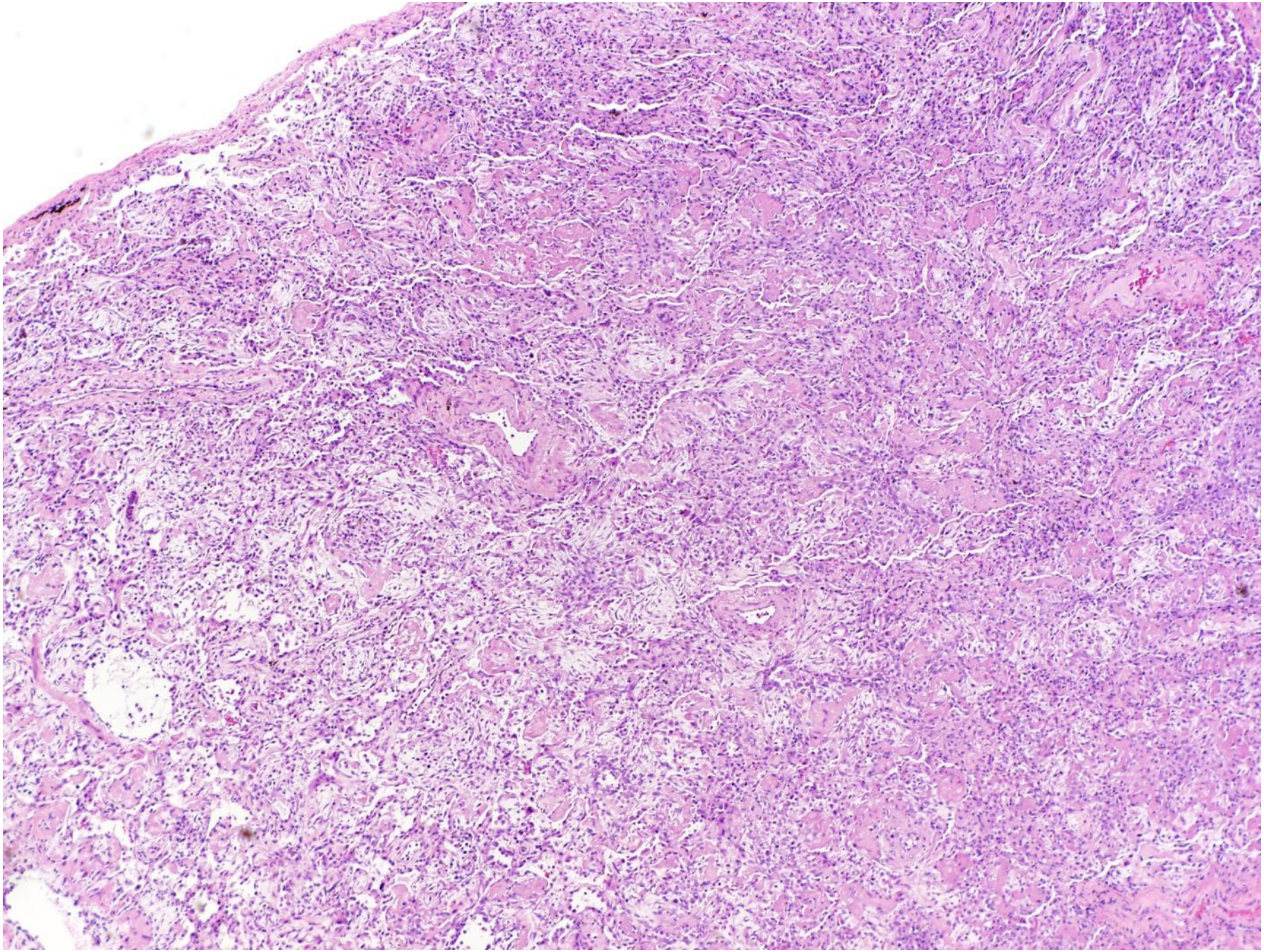

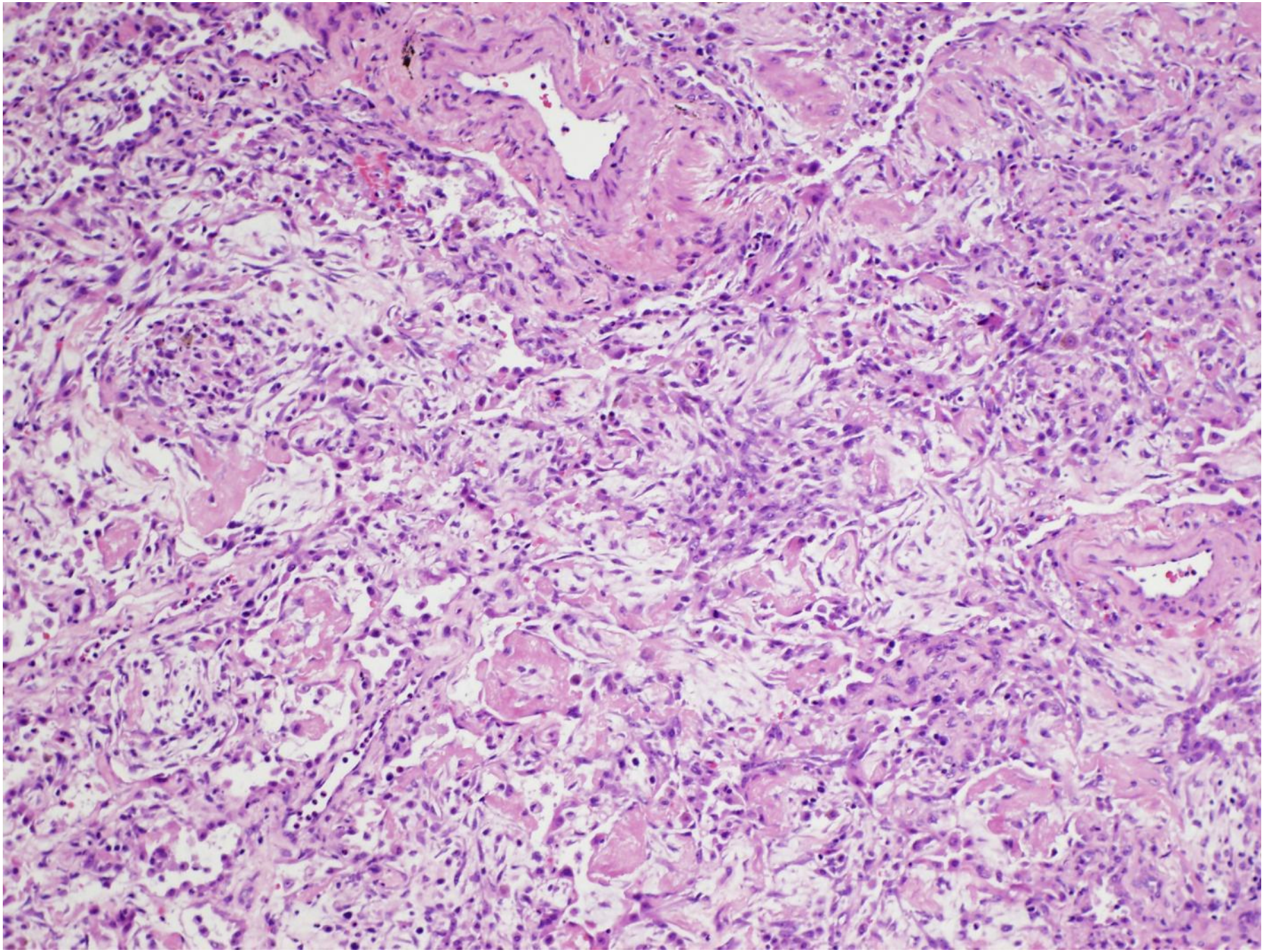

Parenchymal lesions

- Lymphoid interstitial pneumonia (LIP)
  - rarely encountered
  - several reclassified as cellular NSIP or lymphoma
  - classically in Sjögren

Parenchymal lesions

- Histopathology of LIP
  - key features
    - diffuse distribution
    - non-granulomatous chronic inflammation
    - alveolar septa predominantly involved